

Imaging findings of a dilated odontoma shaped type II dens in dente in a mesiodens

Hallazgos imagenológicos de dens in dente tipo II con formato de odontoma dilatado en un mesiodiente

Caio Belém Rodrigues Barros Soares,^I Camila de Moraes e Santiago,^{II} Flávia Maria de Moraes Ramos-Perez,^I Gabriella Lopes de Rezende Barbosa,^{III} Marcelo Augusto Oliveira de Sales,^{IV} Frederico Sampaio Neves^V

^I Department of Oral Radiology. School of Dentistry. Federal University of Pernambuco. Recife, PE, Brazil.

^{II} DDs, private practice.

^{III} Department of Oral Radiology. Federal University of Uberlândia. Uberlândia, MG, Brazil.

^{IV} Department of Oral Radiology. Federal University of Paraíba. João Pessoa, PB, Brazil.

^V Department of Oral Radiology. School of Dentistry. Federal University of Bahia. Salvador, BA, Brazil.

ABSTRACT

Introduction: there are three types of dens in dente: Type I, minimal invagination confined to the crown of the tooth which does not extend beyond the amelocemental junction; Type II, invagination extends to the pulp chamber, but remains within the root canal with no communication with the periodontal ligament; and Type III, invagination extends to the root of the affected tooth, beyond the cemento-enamel junction. The term dilated odontoma is used to describe the most severe variant of invagination (Type III), which is characterized by crown and/or root dilation of the affected tooth.

Objective: describe a rare case of a dilated odontoma shaped dens in dente in a mesiodens and its imaging findings, diagnosed by cone beam computed tomography.

Case presentation: a 14-year-old male patient was referred for radiographic examination of the mandible and maxilla to determine the cause of abnormal tooth eruption chronology. Two mesiodens were found on the maxilla. Due to the peculiar morphology of the mesiodens on the right side, cone beam computed tomography was performed. Multiplanar reconstructions revealed an oval structure on the eruption path of the upper right central incisor, in contact with its palatal surface. Coronal and sagittal reconstructions showed that invagination extended beyond the cemento-enamel junction, without any additional apical/lateral formation.
Conclusions: the final diagnosis was dilated odontoma shaped type II dens invaginatus in a mesiodens.

Keywords: dens in dente; supernumerary tooth; cone beam computed tomography.

RESUMEN

Introducción: existen tres categorías de dens in dente: Tipo I, invaginación mínima confinada a la corona del diente y que no se extiende más allá de la unión amelo-cementaria; Tipo II, la invaginación se extiende a la cámara de la pulpa, pero permanece dentro del canal de la raíz, sin comunicación con el ligamento periodontal; y Tipo III, la invaginación se extiende a la raíz del diente afectado, más allá de la unión cemento-esmalte. El término odontoma dilatado se utiliza para describir la variante más grave de la invaginación (tipo III), que se caracteriza por la dilatación de la corona y/o la raíz del diente afectado.

Objetivo: describir un caso raro de un dens in dente con formato de odontoma dilatado en un mesiodiente y sus hallazgos imagenológicos, diagnosticados mediante tomografía computarizada de haz cónico.

Presentación del caso: paciente varón, 14 años de edad, fue enviado a un servicio de Radiología Odontológica con el fin de determinar la causa de anómala cronología de la erupción dental en maxilar superior y mandíbula. Dos mesiodientes fueron identificados en el maxilar superior. El mesiodiente del lado derecho llamó la atención debido a su peculiar morfología, por lo que se realizó la tomografía computarizada de haz cónico. Las reconstrucciones multiplanares revelaron una estructura ovalada ubicada en el trayecto de erupción del incisivo central superior derecho, en contacto con su superficie palatina. Reconstrucciones coronales y sagitales demostraron que era posible identificar la extensión de la invaginación más allá de la unión cemento-esmalte, sin constitución de forma apical/lateral accesoria.

Conclusiones: el diagnóstico final fue dens invaginatus tipo II en forma de odontoma dilatado en un mesiodiente.

Palabras clave: dens in dente; diente supernumerario; tomografía computarizada de haz cónico.

INTRODUCTION

Dens in dente or dens *invaginatus*, is a developmental malformation with a broad spectrum of morphological variation and controversial etiology. It consists of an epithelial invagination originated in the crown or root of a developing tooth.

There are three well-established categories according with the studies conducted by Oehlers.¹ On his paper published in 1957, the author states that there are three main types depending on the depth of invagination and crown morphology of committed tooth: (1) Type I, minimal enamel-lined invagination confined within the crown of the tooth and does not extend beyond the amelo-cemental junction. (2) Type II, the invagination is enamel-lined and extends into the pulp chamber, but remains within the root canal with no communication with the periodontal ligament. (3) And type III, which is separated into two sub variations - (A) when the invagination extends through the root and communicates laterally with the periodontal ligament space through an accessory foramen. There is usually no communication with the pulp, which lies compressed within the root - and (B), the invagination extends through the root and communicates with the periodontal ligament at the apical foramen. There is usually no communication with the pulp.

The term dilated Odontoma is used to describe the most severe variation of invagination (type III), which is characterized by crown and/or root dilation of the affected tooth. This severe invagination leads to a complete inversion of dental hard tissues, usually followed by a central soft and/or hard tissue presence. Radiographically, dilated Odontoma shows a calcified circular or oval structure with a central radiolucent shadow.²

The clinical relevance of this condition is due to the high possibility of pulp necrosis, caused by the communication between oral cavity and pulp tissues that allows the direct penetration of pathogenic microorganisms through a thin layer of enamel and dentin.^{3,4}

Dental anomalies, such as dens in dente, are commonly diagnosed during routine radiographic exams. However, conventional radiographic exams do not allow tridimensional visualization of dental structures, hence difficulting diagnosis and treatment planning when facing this abnormality. In many cases, a more refined and precise imaging method, such as cone beam computed tomography (CBCT) is needed.^{5,6}

Most of the available data on this pathology comes from case reports and the known information is still limited, which makes further information important in order to delineate the profile of the condition. Therefore, the aim of the present study was to present a rare occurrence of a dilated Odontoma shaped dens in dente in a mesiodens and its imaginological findings, diagnosed by cone beam computed tomography.

CASE REPORT

All the information and collected data of the present paper was authorized for publication on scientific journals. To ensure the ethical aspect, a signed consent form was obtained from the patient and its legal tutors.

A 14-year-old white male patient was referred to a private Dental Radiology clinic for radiographic examination in order to evaluate the cause of abnormal tooth eruption in the mandible and anterior region of the maxilla. It was observed, on panoramic radiograph (Fig. 1), the presence of seven supernumerary teeth. Three supernumerary teeth in the maxilla: two mesiodens erupted in the central incisors region, and one unerupted between right canine and first premolar. As well as four unerupted supernumerary in the mandibular premolar area: two on the left side and two on the right side. Root development criteria was used in order to identify the permanent teeth located bilaterally on mandibular premolar area (Fig. 1). The mesiodens erupted on the right side drew attention due to its abnormal morphology, presenting an oval shaped structure with a central radiolucent shadow.

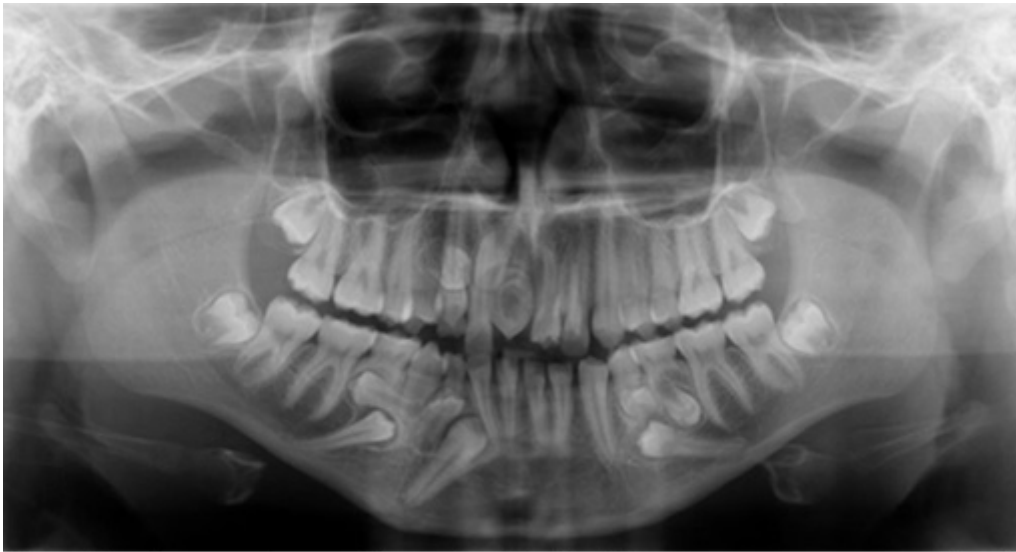

Fig. 1. Panoramic radiograph highlighting supernumerary teeth (yellow), both mesiodens included, and impacted permanent teeth (black). The unusual morphology of the mesiodens located to the right side can.

Given the unusual shape of the right mesiodens and the need to know of its relation with adjacent teeth and relevant anatomical structures, CBCT exam was performed. For this purpose, CBCT machine iCAT Next Generation® (Imaging Sciences International, Pennsylvania, USA) with iCAT visionQ® software were used.

The evaluation of multiplanar reconstructions (MPRs) took place on a light dimmed and quiet room with the iCAT Workstation Dental Imaging System (Powered by XoranCat™ technology - Xoran® technologies) software. The MPRs were evaluated with a 0.25 mm thickness and sharpen mild filter.

The MPRs showed an oval shaped structure of larger proportions than the adjacent teeth, located on the eruption path of the upper right central incisor in contact with its palatal surface. Coronal and sagittal reconstructions showed a dilated invagination that could be identified beyond the amelo-cemental junction, without apical/lateral foramen formation (Fig. 2).

Axial, coronal and sagittal reconstructions also revealed compression of the pulp chamber and discrete communication with the invagination in the middle third of the root on mesial surface. It was also detected the presence of calcified focus inside the invagination, as well as an osteolytic image in the periapical region of the affected tooth (Fig. 3). The diagnosis, based on the CBCT images of the examined tooth, was dilated Odontoma shaped dens in dente Type II in an impacted mesiodens. The patient was, then, referred to a bucomaxillofacial surgery private service for surgical treatment.

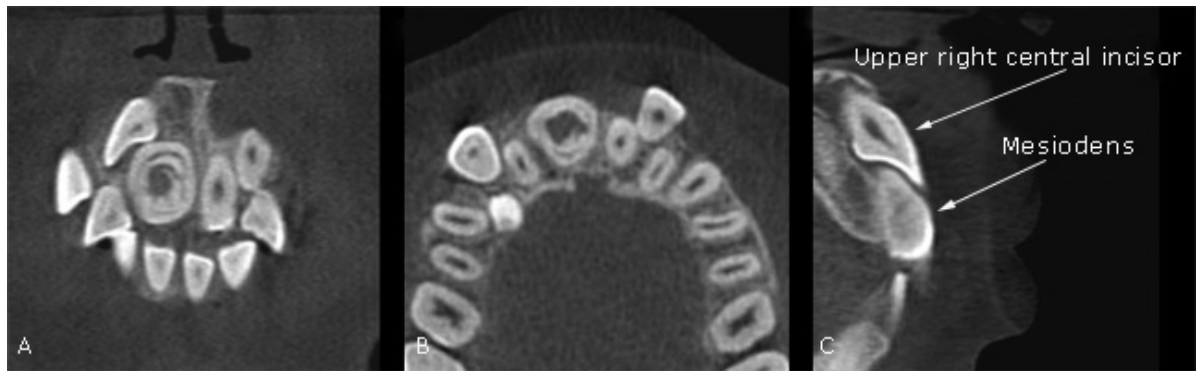

Fig. 2. Axial (A), coronal (B) and sagittal (C) reconstructions showing a mesiodens with an invagination.

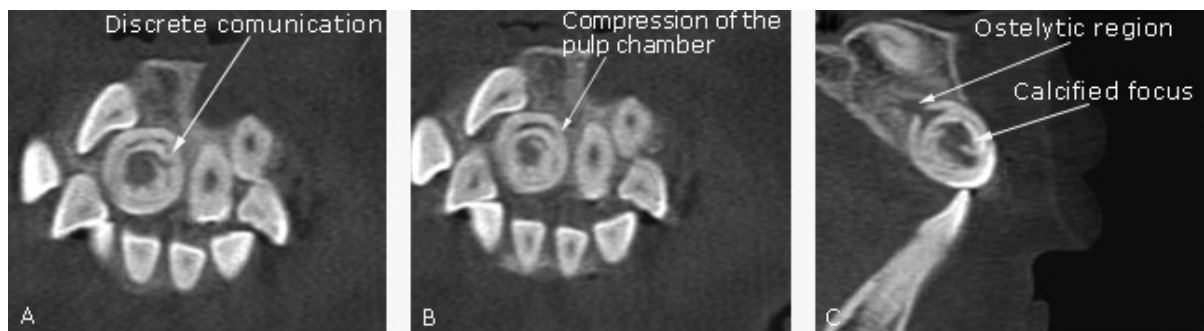


Fig. 3. Coronal and sagittal reconstructions showing particular features of the invaginated mesiodens.

Table. Case reports of the association between mesiodens and dens invaginatus

References	Case number	Gender/age of the patient	Oehlers classification	Imaging modality	Presence of an osteolytic image in the periapical region
<i>Archer & Silverman (1950)</i>	1; 2	Unavailable/9 years	Unavailable	Periapical radiograph; Occlusal radiograph	No
<i>Serrano (1991)</i>	3	Female/12 years	Unavailable	Periapical radiograph	No
<i>Sannomiya et al. (2007)</i>	4	Female/8 years	Type II	Panoramic radiograph; periapical radiograph	No
<i>Sannomiya et al. (2007)</i>	5; 6	Male/16 years	Type II	Periapical radiograph	No
<i>Sulabha & Sameer (2012)</i>	7; 8	Unavailable/13 years	Type I	Panoramic radiograph; periapical radiograph	No
<i>Nalawade et al. (2013)</i>	9	Male/13 years	Type II	Panoramic radiograph; periapical radiograph	No
<i>Cantín, Fonseca (2013)</i>	10	Female/9 years	Type II	Panoramic radiograph; periapical radiograph; CBCT	No
<i>Soares et al. (present case)</i>	11	Male/white/14 years	Type II/dilated Odontoma shaped	Panoramic radiograph; CBCT	Yes

DISCUSSION

Dens in dente is a structural development anomaly of the tooth. This abnormality presents itself as an epithelial invagination on the crown and/or root portion.¹ The prevalence is uncertain in the literature due to the variety of methods applied in each study. On the other hand, it seems to be of common agreement that the most affected tooth is the upper lateral incisor.^{1,7,8}

A PUBMED research was conducted - including only articles published in the English literature - to review the literature for case reports of dens in dente in association with mesiodens tooth (table). The keywords "dens in dente", "dens invaginatus", "dilated odontoma", dilated odontome", "supernumerary tooth" and "mesiodens" were used for this purpose. A total of ten cases of dens in dente associated with a mesiodens have been described. Characteristics of dens in dente were found in all case reports. The CBCT was used for the final diagnosis only on the present paper and *Cantín & Fonseca*⁹ cases, being the present case the first report the presence of an osteolytic image in the periapical region of the affected mesiodens. Also, only the present case report and the one made by *Nalawade et al.*¹⁰ presented a dilated Odontoma shaped dens in dente on a mesiodens.

Complications related to the presence of mesiodens are a common clinical finding in the dental practice.¹⁰⁻¹³ All cases reported, described in [table](#), presented complications related to the mesiodens, such as impaction of permanent teeth.^{4,9-16} Impaction of a permanent maxillary tooth, right central incisor, was also found in the present case report.

Twelve cases of oval shaped radiopaque shadows with a radiolucent central area were reported in the recent literature, five of them located in the mandibular region^{2,17,18-20} and seven located in the maxilla.^{18,21-27} The radiographical/imaginological diagnostic criteria used on the mentioned cases was based on type of invagination, presence of severe inversion of the hard dental tissues, dilation of the crown and central radiolucent area. Similar criteria were used for the present study in order to establish dilated Odontoma as a final diagnosis. Some studies also used histopathological exams to confirm their diagnosis.^{18,19,21,22} A type III dens in dente was usually associated with the dilated Odontoma.^{21,22,24,25} Nevertheless, the present case report found a dilated Odontoma on a type II dens in dente. Similar diagnosis was found by *Nalawade et al.*¹⁰

The characteristics found on the present study combine some of the presented by previous reports in relation to the morphological deformity of the affected tooth. Although, a less severe involvement was observed, since it was possible not only to differentiate the crown from the radicular portion, but also identify a compressed pulp chamber partially separated from the central radiolucent area representing the invagination.^{2,17,19}

Clinically, a wide range of pulp and periodontal changes can be associated with the presence of dens in dente. The teeth affected by this anomaly are more susceptible to dental cavities, pulp infection and necrosis, since the modified enamel and dentin structure may easily allow invasion of microorganisms and their toxic products in the pulp cavity.^{22,26,28} On the present report, an osteolytic image in the periapical region was observed associated with the mesiodens, which may be explained by the existing communication between invagination and pulp tissue. The visualization of the lesion was only possible by the use of the affordable, user-friendly, and readily accepted MPRs of CBCT.^{26,28,29} Osteolytic image was also detected on the dilated Odontomas reported by *Jayachandran et al.*,¹⁸ *Pradeep et al.*²⁶ and *Sharma et al.*²⁴

In conclusion, such cases pose a challenge to the clinician in the diagnosis as well as in treatment and treatment planning. Due to diagnostic limitations of conventional radiographs, characteristics of the dilated Odontoma, such as internal features and extent could not be observed in detail. In our case, CBCT was fundamental to the final diagnosis of mesiodens affected by dilated Odontoma, a rare association described in the literature.

Conflicts of interest

The authors of the present paper hereby declare that there were no conflicts of interest involved in the analysis, discussion and composition of this article.

BIBLIOGRAPHIC REFERENCES

1. Oehlers FA. Dens invaginatus (dilated composite odontome). I. Variations of the invagination process and associated anterior crown forms. *Oral Surg Oral Med Oral Pathol.* 1957;10:1204-18.
2. Matsusue Y, Yamamoto K, Inagake K, Kirita T. A dilated odontoma in the second molar region of the mandible. *Open Dent J.* 2011;5:150-3.
3. Mupparapu M, Singer SR. A review of dens invaginatus (dens in dente) in permanent and primary teeth: report of a case in a microdontic maxillary lateral incisor. *Quintessence Int.* 2006;37:125-9.
4. Sannomiya EK, Asaumi J, Kishi K, Dalben Gda S. Rare associations of dens invaginatus and mesiodens. *Oral Surg Oral Med Oral Pathol Oral Radiol Endod.* 2007;104:e41-4.
5. Neves FS, Pontual AA, Campos PSF, Frazão MAG, Almeida SM, Ramos-Perez FMM. Radicular dens invaginatus in a mandibular premolar: cone-beam computed tomography findings of a rare anomaly. *Oral Radiol.* 2013;29:70-3.
6. Jaya R, Mohan Kumar RS, Srinivasan R. A rare case of dilated invaginated odontome with talon cusp in a permanent maxillary central incisor diagnosed by cone beam computed tomography. *Imaging Sci Dent.* 2013;43:209-13.
7. Mupparapu M, Singer SR, Goodchild JH. Dens evaginatus and dens invaginatus in a maxillary lateral incisor: report of a rare occurrence and review of literature. *Aust Dent J.* 2004;49:201-3.
8. Alani A, Bishop K. Dens invaginatus. Part 1: classification, prevalence and aetiology. *Int Endod J.* 2008;41:1123-36.
9. Cantín M, Fonseca GM. Dens invaginatus in an impacted mesiodens: a morphological study. *Rom J Morphol Embryol.* 2013;54:879-84.
10. Nalawade TM, Pateel D, Mallikarjuna R, Gunjal S. Dens invaginatus type II associated with an impacted mesiodens: a 3-year follow-up. *BMJ Case Rep.* 2013 jul 26. doi: 10.1136/bcr-2013-200211.
11. Garvey MT, Barry HJ, Blake M. Supernumerary teeth--an overview of classification, diagnosis and management. *J Can Dent Assoc.* 1999;65:612-6.
12. Proff P, Fanghänel J, Allegrini S Jr, Bayerlein T, Gedrange T. Problems of supernumerary teeth, hyperdontia or dentes supernumerarii. *Ann Anat.* 2006;188:163-9.
13. Sanei-Moghaddam A, Hyde N, Williamson P. Endoscopic removal of a supernumerary tooth from the nasal cavity in an adult. *Br J Oral Maxillofac Surg.* 2009;47:484-5.

14. Archer WH, Silverman LM. Double dens in dente in bilateral rudimentary supernumerary central incisors (mesiodens). *Oral Surg Oral Med Oral Pathol.* 1950;3:722-6.
15. Serrano J. Triple dens invaginatus in a mesiodens. *Oral Surg Oral Med Oral Pathol.* 1991;71:648-9.
16. Sulabha AN, Sameer C. Association of mesiodentes and dens invaginatus in a child: a rare entity. *Case Rep Dent.* 2012;2012:198032.
17. Cuković-Bagić I, Macan D, Dumancić J, Manojlović S, Hat J. Dilated odontome in the mandibular third molar region. *Oral Surg Oral Med Oral Pathol Oral Radiol Endod.* 2010;109:e109-13.
18. Jayachandran S, Kayal L, Sharma A. Dilated odontoma: A report of two cases from a radiological perspective. *Contemp Clin Dent.* 2016;7(1):107-10.
19. Almeida B, Silva A, Pereira M, Silva M, Nunes S. Case report of a dilated odontome in the posterior mandible. *Int J Surg Case Rep.* 2016;20:14-6. doi: 10.1016/j.ijscr.2015.12.048. Epub 2016 Jan 7.
20. Halawar SS, Satyakiran G, Krishnanand P, Prashanth R. Dens invaginatus (dilated odontome) in mandibular canine. *J Oral Maxillofac Pathol.* 2014 Sep;18(Suppl 1):S157-62.
21. Sebastian AA, Ahsan A, George AJ, Aby J. An unusual triad: Bilateral dilated odontoma, hypodontia and peg laterals. *Dent Res J (Isfahan).* 2013;10:674-7.
22. Clarke P, Longridge N, Gartshore L. A multidisciplinary management of a type III dens invaginatus in a maxillary permanent canine. *Eur Arch Paediatr Dent* 2016;17(2):131-6.
23. Kallianpur S, Sudheendra U, Kasetty S. Dens invaginatus (Type III B). *J Oral Maxillofac Pathol.* 2012;16(2):262-5.
24. Sharma G, Nagra A, Singh G. An Erupted Dilated Odontoma: A Rare Presentation. *Case Rep Dent.* 2016;2016:9750947.
25. Syed AZ, Venkata AP, Mendes RA. Dilated odontoma: an incidental finding. *BMJ Case Rep.* 2015. doi: 10.1136/bcr-2015-212594.
26. Pradeep K, Charlie M, Kuttappa MA. Conservative Management of Type III Dens in Dente Using Cone Beam Computed Tomography. *J Clin Imaging Sci.* 2012;2:51.
27. Wall A, Ng S, Djemal S. The value of cone beam CT in assessing and managing a dilated odontome of a maxillary canine. *Dent Update.* 2015 Mar;42(2):126-8.
28. McClammy TV. Endodontic applications of cone beam computed tomography. *Dent Clin North Am.* 2014 Jul;58(3):545-59. doi: 10.1016/j.cden.2014.03.004.

29. Juneja R, Kumar V. Endodontic Management of a Mandibular Incisor Exhibiting Concurrence of Fusion, Talon Cusp and Dens Invaginatus using CBCT as a Diagnostic Aid. J Clin Diagn Res. 2016 Feb;10(2):ZD01-3.

Recibido: 18 de julio de 2016.
Aprobado: 22 de enero de 2017.

Caio Belém Rodrigues Barros Soares. School of Dentistry, Federal University of Pernambuco. Professor Moraes Rego Avenue, 1235, Cidade Universitária, Recife, PE, Brazil. Zip Code: 50670-901. E-mail: caiorodriguesmd@gmail.com