



CLINICAL RESEARCH:

Cephalometric Evaluation of the Relationship Between Cervical Vertebral Morphology and Anomalies and the Cranial Base Angle in Different Facial Types and Skeletal Classes

Evaluación cefalométrica de la relación entre la morfología vertebral cervical y las anomalías y el ángulo de la base del cráneo en diferentes tipos faciales y clases esqueléticas

Farzaneh Ostovarrad¹ <https://orcid.org/0000-0002-2618-6056>; Masoumeh Faghani² <https://orcid.org/0000-0001-6011-1958>
Zahra Yousefi³ <https://orcid.org/0000-0001-7598-0478>; Zahra Tadayoni⁴ <https://orcid.org/0000-0002-8813-1819>
Maryam Tofangchiha⁵ <https://orcid.org/0000-0002-5515-2189>; Ippolito Caputo⁶ <https://orcid.org/0009-0009-2577-4313>
Francesco Pagnoni⁶ <https://orcid.org/0000-0003-1726-2130>; Rodolfo Reda⁷ <https://orcid.org/0000-0003-1532-6524>
Luca Testarelli⁸ <https://orcid.org/0000-0003-3904-3000>

¹Assistant professor, Department of Oral and Maxillofacial Radiology, School of Dentistry, Guilan University of Medical Sciences, Rasht, Iran.

²Associated professor, Department of Anatomical Sciences, School of Medicine, Guilan University of Medical Sciences, Rasht, Iran.

³Assistant professor, Department of Oral and Maxillofacial Radiology, Dental Caries Prevention Research Center, Qazvin University of Medical Sciences, Qazvin, Iran.

⁴Post-graduate Student, School of Dentistry, Guilan University of Medical Sciences, Rasht, Iran.

⁵Professor, Department of Oral and Maxillofacial Radiology, Dental Caries Prevention Research Center, Qazvin University of Medical Sciences, Qazvin, Iran.

⁶Student, Department of Oral and Maxillofacial Sciences, Sapienza University of Rome, 00161 Rome, Italy.

⁷PhD, Department of Oral and Maxillofacial Sciences, Sapienza University of Rome, 00161 Rome, Italy.

⁸Associated professor, Department of Oral and Maxillofacial Sciences, Sapienza University of Rome, 00161 Rome, Italy.

Correspondence to: Zahra Yousefi - zahrayousefi71@yahoo.com

Received: 12-X-2023

Accepted: 29-XI-2023

ABSTRACT: This study examines the morphology and common anomalies of the cervical vertebrae in different skeletal classes and facial types. This cross-sectional study was conducted on 137 lateral cephalometric images of patients aged 18-55 years. The images were evaluated for fusion and posterior arch deficiency as the two most common anomalies along with cervical vertebral morphology (dense angle, the height of the posterior arch of the atlas, the external anterior posterior diameter of the atlas, and the cranial base angle). Data were categorized into three skeletal classes based on the Wits analysis and the ANB angle and also three facial types based on the SN-MP angle. These calculations were performed in SPSS 22 at the significance level of $P < 0.05$. The height of the posterior arch of the atlas was directly and significantly related to age and increased with it. The mean external anterior posterior diameter of C1 was higher in men and in the hypodivergent group. As for the other factors,



including cervical spine anomalies, no significant relationship was observed with age, sex, skeletal classes, facial types, and the cranial base angle. Moreover, the mean morphology of the cervical spine was not significantly associated with skeletal classes. Based on the results, the height of the posterior arch of the atlas was associated with age and increased along with it. Moreover, the mean external anterior posterior diameter of the atlas was greater in men and in hypodivergent individuals.

KEYWORDS: Abnormalities; Cephalometry; Cervical vertebrae; Face; Skeletal; Cranial base angle.

RESUMEN: Este estudio examina la morfología y anomalías comunes de las vértebras cervicales en diferentes clases esqueléticas y tipos faciales. Este estudio transversal se realizó en 137 imágenes cefalométricas laterales de pacientes de 18 a 55 años. Las imágenes fueron evaluadas para detectar fusión y deficiencia del arco posterior como las dos anomalías más comunes junto con la morfología vertebral cervical (ángulo denso, la altura del arco posterior del atlas, el diámetro anterior externo posterior del atlas y el ángulo de la base del cráneo). Los datos se clasificaron en tres clases esqueléticas según el análisis de Wits y el ángulo ANB y también en tres tipos faciales según el ángulo SN-MP. Estos cálculos se realizaron en SPSS 22 con un nivel de significancia de $P < 0,05$. La altura del arco posterior del atlas estaba directa y significativamente relacionada con la edad y aumentaba con ella. El diámetro anteroposterior externo medio de C1 fue mayor en los hombres y en el grupo hipodivergente. En cuanto a los demás factores, incluidas las anomalías de la columna cervical, no se observó una relación significativa con la edad, el sexo, las clases esqueléticas, los tipos faciales y el ángulo de la base del cráneo. Además, la morfología media de la columna cervical no se asoció significativamente con las clases esqueléticas. Según los resultados, la altura del arco posterior del atlas se asoció con la edad y aumentó con ella. Además, el diámetro anteroposterior externo medio del atlas fue mayor en hombres y en individuos hipodivergentes.

PALABRAS CLAVE: Anomalías; Cefalometría; Vértebras cervicales; Cara; Esquelético; Ángulo de la base del cráneo.

INTRODUCTION

Abnormal vertebral morphology is caused by defects in vertebral segmentation and/or vertebral development (1, 2). Since most of these abnormalities are asymptomatic, they may only emerge with age or upon the incidence of a trauma (3-5).

The most common cervical vertebral anomalies include fusion and posterior arch deficiency (PAD) (3). Although it is possible to observe cervical vertebral anomalies in healthy individuals with normal occlusion and normal craniofacial morphology, some studies have found an association between upper cervical vertebral malformations and cleft lip and palate (6), condylar hypoplasia (7), skeletal deep bite (8), skeletal mandibular overjet, and skeletal open bite (9).

Sonnesen noted the relationship between cervical column morphology and head and neck posture and disclosed that fusion is associated with head and neck posture (10). Significant correlations have also been reported between fusion and a large cranial base angle, fusion and retrognathia, and fusion and inclination of the jaws in patients with severe skeletal malocclusion (11). These findings indicate a relationship between cervical spine fusion and craniofacial morphology, including the cranial base (10).

Lateral cephalometric imaging is the most common form of radiography used in orthodontic clinics (12). It is primarily used to evaluate growth, development, and morphometric craniofacial and maxillomandibular relationships, dental structures, and cervical vertebrae morphology in order to assess skeletal maturity; however, this imaging technique can also be used to study various anomalies of the cervical vertebrae (4,12).

Considering the relationship between the cervical spine and head position and the relationship between head and craniofacial morphology,

including the mandibular rotation pattern, we may deduce a relationship between cervical morphology and the vertical dimensions of the face (6). Since the nature of this relationship is not well understood, and due to the inadequate studies on this subject and the significance of the issue. Therefore this study aimed to assess the morphology and common anomalies of the cervical vertebrae in different skeletal classes and facial types. The present study used lateral cephalometric images as the most common modality in orthodontics to investigate the relationship between fusion and PAD as common cervical anomalies as well as the relationship of cervical vertebral morphology and cranial base angle with different facial types and skeletal classes. If there is a relationship between these factors, a closer examination of the spine in lateral cephalometry can be recommended for individuals with occlusal deviations in orthodontic treatment.

MATERIALS AND METHODS

The current cross-sectional study was approved by the Research Ethics Committee of Guilan University of Medical Sciences (IR.GUMS.REC.1400.532) and was conducted on 137 lateral cephalometric images. Informed consent was taken from the patients with regard to the use of their cephalometric data. Individuals aged 18-55 years with permanent teeth and good-quality images recording their C1 to C3 vertebrae were included. Those with a history of trauma to or surgery on the cervical vertebrae, craniofacial abnormalities, or musculoskeletal defects were excluded.

The patients were divided into three facial types based on the SN-MP angle: Hypodivergent ($<26^\circ$), normodivergent ($26-34^\circ$), and hyperdivergent ($>34^\circ$). Based on the Wits analysis and the ANB angle, they were also divided into three skeletal classes (13). The cranial base angle was determined by measuring the angle between nasion sella and sella basion.

The morphology of the cervical spine was determined by measuring the external anterior posterior diameter of C1, the height of the posterior arch of the atlas, and the dense angle (between the axis of the dense and the occlusal plane) (Figure 1). As for cervical spine anomalies, the two common cases of fusion (merging of one cervical vertebra with another and the lack of radiolucency on these surfaces) and PAD (cases with a posterior atlas arch length of <4 mm) were examined (10, 13) (Figure 2).

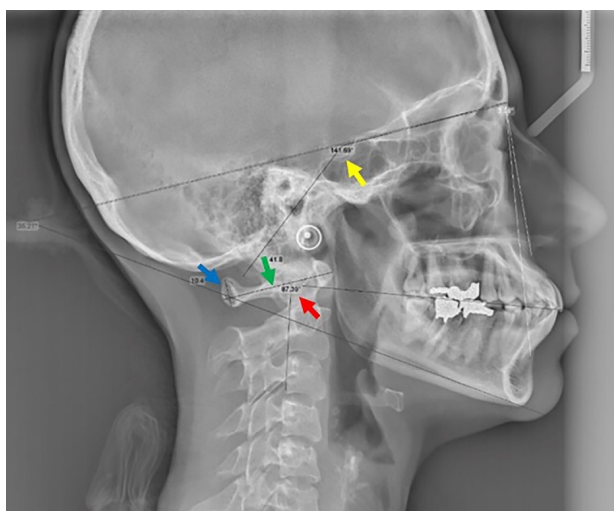


Figure 1. Analysis of the lateral cephalometric image and measurement of study parameters. Cranial base angle (yellow arrow), the height of the posterior arch of the atlas (blue arrow), the external anterior posterior diameter of the atlas (green arrow), the dense angle (red arrow).

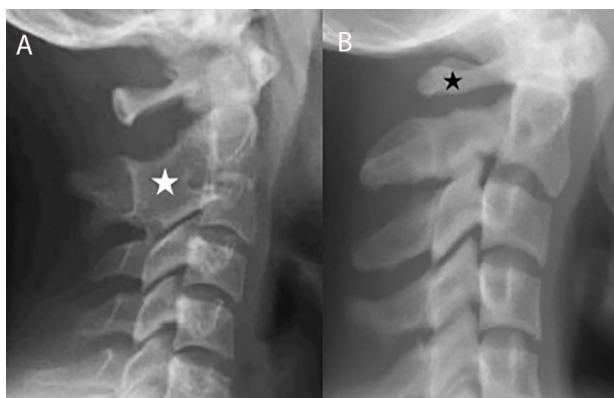


Figure 2. A. Fusion of C2 and C3 vertebrae (white asterisk*). B. Posterior arch deficiency (PAD) (black asterisk*).

All lateral cephalometric images were taken by a calibrated Planmeca Scara III (Helsinki, Finland) with the patient's Frankfurt plane parallel to the ground. Exposure conditions differed according to each patient's condition. Observations and measurements were made in Scanora 5 on a 22-inch monitor by a maxillofacial radiologist. To ensure diagnosis reliability, ten samples were re-examined at a seven-day interval and agreement about the diagnosis was ensured based on Kappa's coefficient (0.82). The minimum acceptable value was 70%.

STATISTICAL ANALYSIS

Descriptive statistics including mean and standard deviation and frequency and percentage were used to describe the data. The normality of the data was assessed using the Shapiro-Wilk test, and the homogeneity of the variance in the study groups was evaluated using Levene's test. To analyze the data, if the assumptions were held, the independent t-test and analysis of variance (ANOVA) (with Tukey's pairwise comparisons) were used for the quantitative variables; if the assumptions were violated, the Kruskal-Wallis test and Spearman's correlation test were used. As for the qualitative variables, the Chi-square test was used if the assumptions were held, and Fisher's exact test was performed if they were not held. These calculations were performed in SPSS 22 (SPSS, Inc., Chicago, IL, USA) at the significance level of $P < 0.05$.

RESULTS

The lateral cephalometric images of 137 patients with a mean age of 22.59 ± 8.53 years were examined, including 99 (72.3%) female and 38 (27.7%) male patients.

Of the 137 patients studied, 33 had cervical vertebral anomalies, including 22 with fusion, ten

with PAD, and one person with both. The mean values of cervical vertebral morphology were 7.73 ± 1.94 and 43.69 ± 3.47 mm for the posterior arch height of the atlas and the external anterior posterior diameter of C1, respectively, and the mean dense angle was $86.10 \pm 9.38^\circ$.

In the studied samples, 15 (10.9%) were hypodivergent, 60 (43.8%) normodivergent, and 62 (45.3%) hyperdivergent.

As for the distribution of skeletal class among the patients, 67 (48.9%) belonged to class I, 55 (40.1%) class II, and 15 (10.9%) class III.

The mean cranial base angle was 128.75 ± 9.91 , with a minimum and maximum of 83 and 188.50° .

Assessing the relationship of morphology with age and sex revealed a direct and significant relationship between the height of the posterior arch of the atlas and age ($r=0.19$, $P=0.026$); that is, the height of the posterior arch of the atlas increased with age. Moreover, a significant relationship was observed between the mean external anterior posterior diameter of C1 and sex

($P<0.001$), such that the mean value was higher in men (45.37 ± 3.87) than in women (43.04 ± 3.09). Nevertheless, there was no significant relationship between cervical vertebral anomalies and age ($P=0.352$) or sex ($P=0.162$).

Different facial skeletal classes did not show any significant relationship with age ($P=0.863$) or sex ($P=0.277$) either.

Table 1 presents the frequency of cervical vertebral anomalies for different facial types and skeletal classes, and no significant difference was observed in any of the cases (Table 1).

Table 2 presents the relationship between morphology, cranial base angle, and different facial types. As shown, the only significant difference was observed in the external anterior posterior diameter of C1; based on Tukey's pairwise comparisons, the hypodivergent group had a higher mean diameter than the other two groups (Table 2).

Table 3 demonstrates the relationship of morphology and cranial base angle with different facial skeletal classes, suggesting no significant relationships in any of the cases (Table 3).

Table 1. The relationship of cervical vertebral anomalies with different facial types and skeletal classes.

Variable	Anomaly N (%)				P value*
	No anomaly	Fusion	PAD	Fusion + PAD	
Facial types	Hypodivergent	14 (93.3)	1 (6.7)	0 (0)	0.100
	Normodivergent	42 (70)	15 (25)	3 (5)	
	Hyperdivergent	48 (77.4)	6 (9.7)	7 (11.3)	
Skeletal classes	CI I	48 (71.6)	13 (19.4)	6 (9)	0.611
	CI II	45 (81.8)	6 (10.9)	3 (5.5)	
	CI III	11 (73.3)	3 (20)	1 (6.7)	

PAD: posterior arch deficiency; * Fisher's Exact Test.

Table 2. The relationship of cervical spine morphology and cranial base angle with different facial types.

Variable		Hypodivergent	Normodivergent	Hyperdivergent	P value
		Mean±SD	Mean±SD	Mean±SD	
Morphology	Height of post. arch of C ₁ (mm)	8.19±2.16	7.99±1.90	7.36±1.90	0.129*
	Lateral outer AP diameter of C ₁ (mm)	46.83±3.46	43.37±2.91	43.23±3.63	0.001*
	Dens angle (degree)	82.98±6.55	84.83±8.56	88.09±10.37	0.062*
Cranial base angle		121.93±16.82	129.41±9.95	129.76±6.74	0.133§

Post: posterior; AP: anterior posterior; SD: standard deviation; * ANOVA; § Kruskal Wallis.

Table 3. The relationship of cervical spine morphology and cranial base angle with skeletal classes.

Variable		CI I	CI II	CI III	P value*
Morphology	Height of post. arch of C ₁ (mm)	7.65±2.20	7.79±1.53	7.86±2.21	0.902
	Lateral outer AP diameter of C ₁ (mm)	43.91±3.65	43.31±3.31	44.10±3.33	
	Dens angle (degree)	85.74±9.80	85.100±8.85	88.11±9.74	
Cranial base angle		129.23±9.88	127.98±10.36	129.39±8.71	0.763

Post: posterior; AP: anterior posterior; *ANOVA.

DISCUSSION

Abnormal vertebral morphology is due to defects in segmentation or the development of the vertebrae (1). Many of these developmental abnormalities may be associated with another systemic disease and, since they are often asymptomatic, they may emerge only with age or upon the incidence of a trauma (3,4). The most common cervical vertebral anomalies include fusion and PAD. In the current study, the prevalence of fusion was 16.1% and the prevalence of PAD 7.3%, and the prevalence of their comorbidity was 0.7%. Meanwhile, in the study by Adisen SR *et al.*, the highest prevalence of anomalies was related to PAD (22.5%) and the lowest to fusion (20.3%) (14). The rates reported by Kamak H. *et al.* were 8.1% for fusion and 5% for PAD (3), and those reported by Anusuya V. *et al.* were 28% for fusion and 36% for PAD (15), which are lower and higher than the prevalence rates reported in the present study, respectively.

The present study found no significant difference between cervical vertebral anomalies and age and sex. Although these results are consistent with those reported by Kamak H. *et al.*, who suggested the absence of a relationship between sex and anomalies (3), Anusuya *et al.* found a significant difference in the rate of different cervical spine anomalies in men and women in all three skeletal classes, such that the prevalence was higher in women and in older ages (15). This disparity could partly be due to the sample size, which was 293 in their study vs. 137 in the current study, and partly due to the studied population. Adisen SR *et al.* reported that, with age, the prevalence of fusion rises in women and the prevalence of PAD rises in men (14); this disparity in findings could be due to the differences in sample size, mean age, and studied population.

Among the studied factors, the height of the posterior arch of the atlas was directly and significantly associated with age and increased with it. Furthermore, the mean external anterior posterior diameter of the atlas was higher in men than women. No correlation was observed between the other morphological factors and age and sex.

The present study did not find any significant relationship between cervical spine anomalies and the different facial skeletal classes. The study by Kamak H. *et al.* (3) also found no relationship between these anomalies and dental malocclusion; however, Meibodi S.E. *et al.* (13) observed a significant difference in the prevalence of fusion between CI I and CI II as well as between CI II and CI III.

According to Watanabe M. *et al.* (16), the height of the posterior arch of the atlas was shorter in CI II than in CI III, while the present study did not find any relationship between cervical vertebral morphology and skeletal classes. This disparity can be attributed to the differences in measurement techniques (CBCT vs. lateral cephalometry) as well as differences in sample size (31 vs. 137). Furthermore, the study by Watanabe M. *et al.* was conducted only on women.

Similar to the present findings, Anusuya V. *et al.* (15) also found no association between cervical vertebral anomalies and different facial types.

In the present research, the mean external anterior posterior diameter of C1 was significantly higher in the hypodivergent group.

The mean skull base angle did not show any significant difference across the skeletal classes. Wilhelm B.M. *et al.* (17) also reported a similar cranial base growth in classes I and II.

Although in the study by Anshuka *et al.*, hyperdivergent and hypodivergent individuals had larger and smaller cranial angles, respectively (6), the current study found no relationship between the cranial base angle and different facial types.

The discrepancies observed in the studies reveal the need for more detailed studies on this subject. The use of CBCT and the assessment of more anomalies in larger samples are recommended for ensuring more accurate results.

Limitation of this study was the lack of sufficient studies on the relationship between the morphology of the cervical spine and age, sex, and different facial types to assess the results this study with other race that this subject highlights the need for further studies on this subject.

CONCLUSIONS

Examining the morphology of the cervical spine showed that the height of the posterior arch of the atlas increases with age, and the external anterior posterior diameter of the atlas was larger in men and in hypodivergent individuals. Due to the inadequacy of studies on cervical anomalies in different skeletal classes and facial types, further research is recommended on this subject. If the relationship between cervical spine anomalies and morphology and different skeletal classes is confirmed on a large scale, the routine examination of the spine could be suggested for occlusal deviations in orthodontic treatments.

AUTHOR CONTRIBUTION STATEMENT

Conceptualization and design: F.O., M.F. and R.R.
Literature review: Z.Y.

Methodology and validation: F.O., M.F., Z.Y., M.T., F.P. and R.R.

Formal analysis: I.C. and L.T.

Investigation and data collection: Z.T., M.T. and F.P.

Resources: I.C.

Data analysis and interpretation: Z.T. and R.R.

Writing-original draft preparation: F.O., M.F., Z.Y., and R.R.

Writing-review & editing: Z.T., M.T. and F.P.

Supervision: L.T.

Project administration: L.T.

REFERENCES

1. Lemire G.T., Beaugard-Lacroix É., Campeau P.M., et al. Retrospective analysis of fetal vertebral defects: Associated anomalies, etiologies, and outcome. *Am J Med Genet A*. 2020; 182 (4): 664-672.
2. Goldstein I., Makhoul I.R., Weissman A., Drugan A. Hemivertebra: prenatal diagnosis, incidence and characteristics. *Fetal Diagn Ther*. 2005; 20 (2): 121-126.
3. Kamak H., Yildirim E. The distribution of cervical vertebrae anomalies among dental malocclusions. *JCVJS*. 2015; 6 (4): 158-161.
4. Ozturk T., Atilla A.O., Yagci A. Cervicovertebral anomalies and/or normal variants in patients with congenitally bilateral absent maxillary lateral incisors. *Angle Orthod*. 2020; 90 (3): 383-389.

5. Bebnowski D., Hänggi M.P., Markic G., Roos M., Peltomäki T. Cervical vertebrae anomalies in subjects with class II malocclusion assessed by lateral cephalogram and cone beam computed tomography. *Eur J Orthod.* 2012; 34: 226-231.
6. Anshuka, Vaswani V., Khajuria S. Assessment and comparison of cervical column morphology and cranial base angle in three different facial types– a cephalometric study. *J Evolution Med Dent Sci* 2020; 9 (36): 2605-2609.
7. Sonnesen L., Pedersen C., Kjaer I. Cervical column morphology related to head posture, cranial base angle and condylar malformation. *Eur J Orthod* 2007; 29 (4): 398-403.
8. Sonnesen L., Kjaer I. Cervical vertebral body fusions in patients with skeletal deep bite. *Eur J Orthod* 2007; 29 (5): 464-470.
9. Sonnesen L., Kjaer I. Cervical column morphology in patients with skeletal Class III malocclusion and mandibular overjet. *Am J Orthod Dentofacial Orthop* 2007; 132 (4): 427.e7-12.
10. Sonnesen L. Associations between the Cervical Vertebral Column and Craniofacial Morphology. *Int J Dent.* 2010; 2010: 295728. doi:10.1155/2010/295728
11. Sonnesen L., Pallisgaard C., Kjær I. Cervical column morphology and craniofacial profiles in monozygotic twins. *Twin Res Hum Genet.* 2008; 11 (1): 84-92.
12. Dinesh A., Mutalik S., Feldman J., Tadinada A. Value-addition of lateral cephalometric radiographs in orthodontic diagnosis and treatment planning. *Angle Orthod.* 2020; 90 (5): 665-671.
13. Meibodi S.E., Meibodi E.M., Meibodi H.M., Kharazifard M.J. Evaluation of the relationship between cervical vertebral morphology and anterior posterior jaw discrepancies. *J Res Dent Sci.* 2013. 10 (2): 118-123.
14. Adisen S.R., Adisen M.Z., Ozdiler F.E. The evaluation of the relationship between cervical vertebral anomalies with skeletal malocclusion types and upper airway dimensions. *Cranio.* 2020;38 (3): 149-157.
15. Anusuya V., Sharan J., Jena A.K. A study of cervical vertebra anomalies among individuals with different sagittal and vertical facial growth patterns. *J Craniovertebr Junction Spine.* 2020; 11 (2): 75-80.
16. Watanabe M., Yamaguchi T., Maki K. Cervical vertebra morphology in different skeletal classes. A three-dimensional computed tomography evaluation. *Angle Orthod.* 2010; 80 (4): 531-536.
17. Wilhelm B.M., Beck F.M., Lidral A.C., Vig K.W. A comparison of cranial base growth in Class I and Class II skeletal patterns. *Am J Orthod Dentofacial Orthop.* 2001; 119 (4): 401-405.