



CASE REPORT:

Immediate Loaded Post Extraction Implant and Connective Graft-Guided Bone Regeneration: A Case Report

Implante postextracción de carga inmediata y regeneración ósea guiada por injerto conectivo:
Reporte de caso

Ivan Calderon¹; Daniel Alvitez-Temoche² <https://orcid.org/0000-0002-3337-4098>

Fran Espinoza-Carhuacho³ <https://orcid.org/0009-0000-4692-942X>; Roman Mendoza² <https://orcid.org/0000-0003-2089-8965>

Franco Mauricio² <https://orcid.org/0000-0003-3658-0302>; Frank Mayta-Tovalino⁴ <https://orcid.org/0000-0002-3280-0024>

¹Academic Department, Faculty of Dentistry, Universidad Nacional Mayor de San Marcos, Lima, Peru.

²Academic Department, Faculty of Dentistry, Universidad Nacional Federico Villarreal, Lima, Peru.

³Grupo de Bibliometria, Evaluacion de evidencia y Revisiones Sistemáticas (BEERS), Human Medicine Career, Universidad Científica del Sur, Lima, Peru.

⁴Vicerrectorado de Investigación, Universidad San Ignacio de Loyola, Lima, Peru.

Correspondence to: Dr. Frank Mayta-Tovalino - fmayta@usil.edu.pe

Received: 12-I-2024

Accepted: 1-III-2024

ABSTRACT: This case report describes the clinical and therapeutic approach used in a 32-year-old female patient with a tooth fracture in tooth 22. The patient, with no history of systemic disease, presented with a chronic periapical lesion and a cervical fracture in the affected tooth. Treatment included atraumatic extraction of the tooth, followed by placement of a 3.75 x 10mm post-extraction implant with immediate loading and guided bone regeneration. The minimally invasive surgical technique was employed using the Dentoflex® drilling sequence. The primary stability of the implant, measured in 37 Newtons of torque, allowed the placement of a prefabricated metal abutment for the subsequent cemented crown. Bone regeneration of the interimplant space was successfully performed, supplemented by connective grafting due to the patient's thin gingival phenotype. Postoperative follow-up, including controls at 7, 14 days and four months, showed a satisfactory conformation of the gingival margin and papillary tissue, consolidating the success of the treatment.

KEYWORDS: Case report; Dental implant; Graft-guided bone; Immediate loaded.



RESUMEN: Este reporte de caso describió el enfoque clínico y terapéutico utilizado en una paciente de 32 años de edad con una fractura dentaria en el diente 22. La paciente, sin antecedentes de enfermedad sistémica, presentaba una lesión periapical crónica y una fractura cervical en el diente afectado. El tratamiento incluyó la extracción atraumática del diente, seguida de la colocación de un implante postextracción de 3,75 x 10mm con carga inmediata y regeneración ósea guiada. Se empleó la técnica quirúrgica mínimamente invasiva utilizando la secuencia de fresado Dentoflex®. La estabilidad primaria del implante, medida en 37 Newtons de torque, permitió la colocación de un pilar metálico prefabricado para la posterior corona cementada. Se realizó con éxito la regeneración ósea del espacio interimplantario, complementada con injerto conectivo debido al fenotipo gingival delgado de la paciente. El seguimiento postoperatorio, incluyendo controles a los 7, 14 días y cuatro meses, mostró una conformación satisfactoria del margen gingival y del tejido papilar, consolidando el éxito del tratamiento.

PALABRAS CLAVE: Caso clínico; Implante dental; Hueso guiado por injerto; Carga inmediata.

INTRODUCTION

Tooth extraction remains a common treatment option in dentistry. However, with the increasing demand for esthetics, especially in the maxillary anterior area, simple extraction is no longer sufficient. Replacement and rehabilitation have become more important and urgent. Dental implants have become the standard for replacing missing teeth or teeth with poor prognosis. Although they were originally used mainly for fixing complex prostheses, in recent years they have been quite successful in replacing a single tooth, especially in the esthetic zone. To ensure the durability and clinical success of an implant, osseointegration is essential. This process allows the implant to bond firmly to the bone and to be asymptomatic during functional stresses (1).

To achieve a natural-looking implant-supported restoration, some experts have stressed the importance of presurgical planning, while others have emphasized proper implant placement. The need to preserve both hard and soft tissues has increased due to the constant pressure for esthetically appealing results. Alveolar bone loss following tooth extraction and implant placement can create significant problems with unfavorable esthetic

consequences. Various investigations have revealed a loss of up to 50% in bone resorption width, as well as a decrease in height of 2-4mm, or an average of 1.24mm. However, this resorption process is highly unpredictable (2).

For many years, bone grafts and bone substitutes have played a crucial role in medicine. Their application in dentistry has seen a surge due to the progression of dental implantology and the necessity to mend craniofacial bone defects (3). The successful insertion of dental implants is contingent upon adequate alveolar bone dimensions. It's projected that nearly half of all dental implant procedures necessitate the use of bone grafts (4). Bone grafts are usually used to provide support, to fill gaps. These are classified into three groups: bone grafts (autograft or xenograft), ceramics/synthetics (hydroxyapatite and tricalcium phosphate) and growth factors (demineralized human bone matrix) (5).

In the repair of bone injuries, including orthopedic or dental defects, cells and growth factors are utilized to hasten the creation of new bone structures. In certain instances, grafts are necessary to substitute the injured tissue and establish a robust link between the implant and the host bone.

Autogenous grafts are the preferred option due to their osteogenic or osteoinductive properties (6). Regeneration entails the complete recovery of damaged tissue to its initial state through various surgical strategies and techniques, such as guided bone regeneration and guided tissue regeneration. Growth factors play a key role in these processes, controlling cell growth and differentiation, as well as wound healing and repair processes. They aid in the migration and proliferation of undifferentiated stem cells at the site of injury and may potentially stimulate the growth and differentiation of mesenchymal stem cells to accelerate bone repair (7,8).

CASE REPORT

This report details a clinical case involving a 32-year-old female patient who sought consultation for a fractured tooth, specifically tooth 22. Despite having no record of systemic diseases or notable medical conditions, an erythematous region was detected in the vestibular area during the local clinical examination of tooth 2.2 (Figure 1). Based on this finding, additional examinations were conducted using panoramic radiography and tomography.

The tomographic analysis revealed the presence of a chronic periapical lesion in tooth 2.2, as well as a cervical fracture in the same (Figure 2). Based on these findings, a treatment plan was formulated that involved extraction of the tooth and placement of a post extraction implant with immediate non-functional loading. In addition, guided bone regeneration was included to address bone loss and ensure implant stability.

Surgery was performed in a minimally invasive manner, following an atraumatic extraction technique with a root traction device (Figure 3 and Figure 4). The absence of a flap allowed for reduced surgical invasiveness and, consequently,

promoted better healing and a faster recovery process. Placement of the implant, a 3.75 x 10mm Dentoflex® with indexed Morse taper, was performed following the manufacturer's recommended drilling protocols and sequences (Figure 5). The primary stability of the implant, with a torque of 37 Newtons, allowed immediate placement of a prefabricated metal abutment for the cemented crown technique.

To address soft tissue loss and optimize final esthetics, guided bone regeneration was performed in the interimplant space (Figure 6). Given the patient's thin gingival phenotype, a connective graft was implemented to ensure adequate stability and formation of the gingival tissues without the need for suturing (Figure 7). The gingival margin conformation and papillary appearance were clinically evaluated and confirmed through controls at 7, 14 days and after four months.

To ensure postoperative comfort and prevention of possible infections, diclofenac and amoxicillin were prescribed. The patient was followed closely in the weeks and months thereafter, allowing a detailed assessment of recovery and tissue adaptation. A follow-up CT scan at four months demonstrated adequate gingival margin conformation and a papillary appearance that met the esthetic and functional goals of treatment (Figure 8 and Figure 9).

Overall, this case exemplifies the importance of a planned, multidisciplinary approach to oral rehabilitation. The combination of atraumatic extraction techniques immediately loaded implant placement, guided bone regeneration and connective grafting allowed successful results in terms of stability, function, and esthetics, reaffirming the relevance of careful planning and execution in implant procedures.

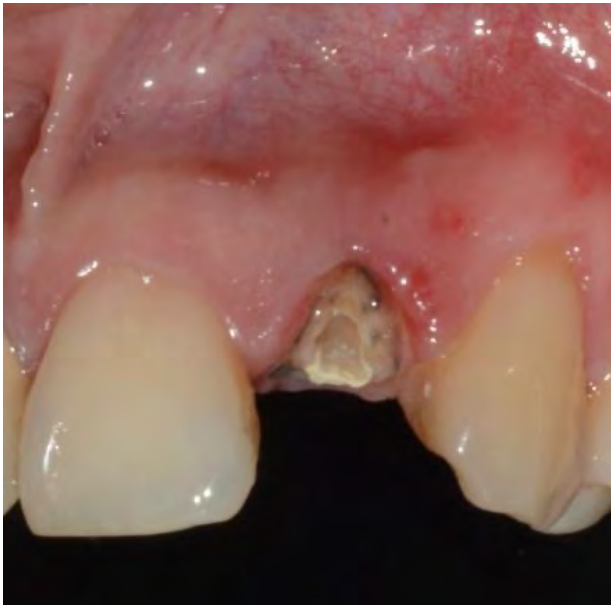


Figure 1. Root remnant prior to extraction.

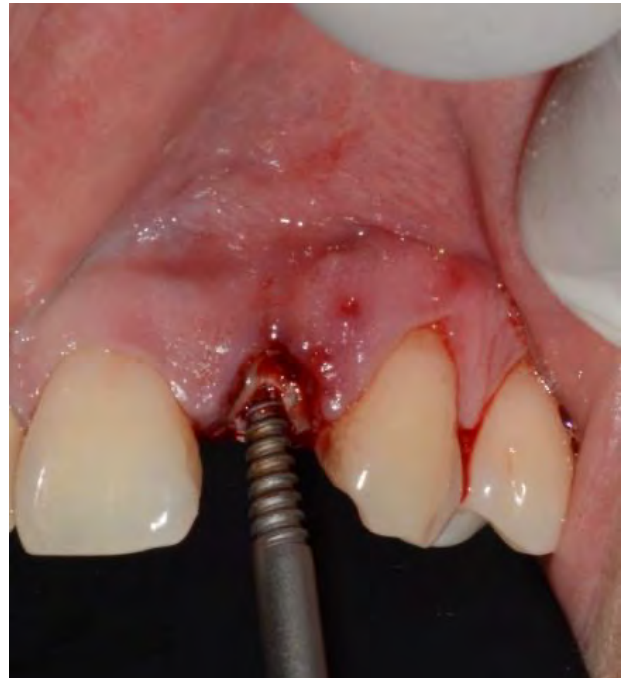

Figure 3. Minimal atraumatic exodontia.

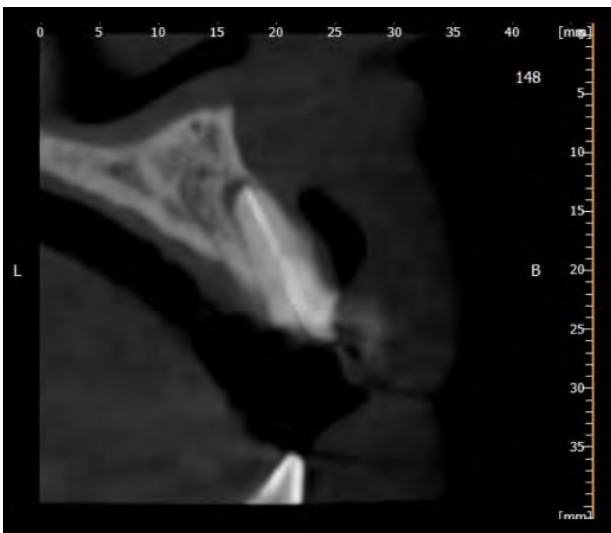


Figure 2. Diagnostic tomography

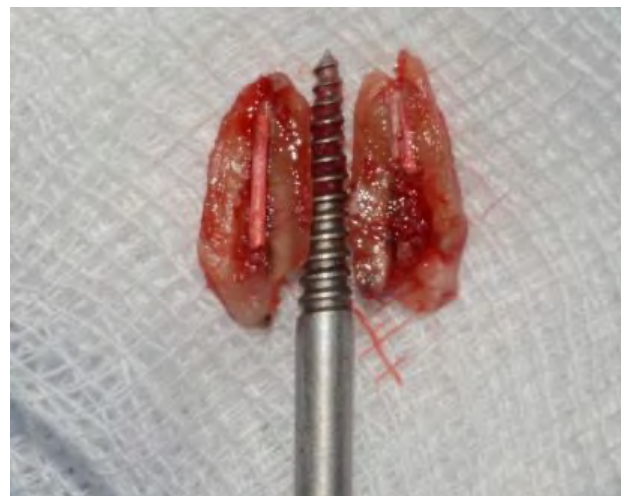

Figure 4. Extracted tooth.

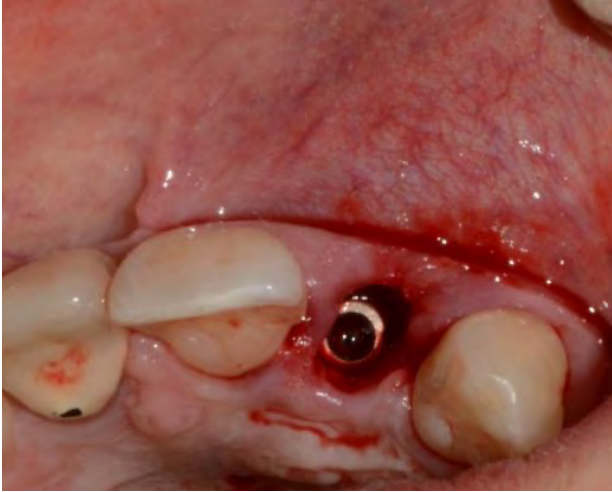

Figure 5. Post extraction implant placement.

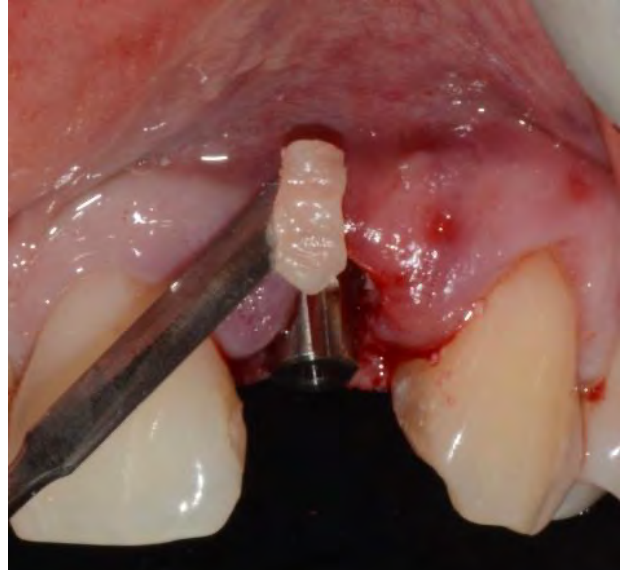


Figure 7. Soft tissue graft placement.

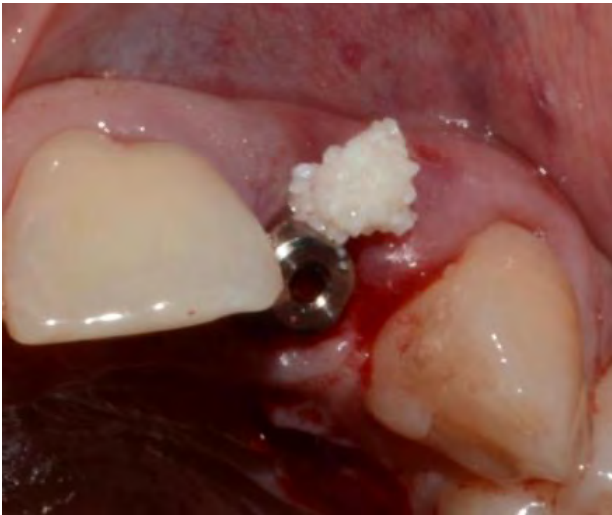

Figure 6. Bone filler in the vestibular gap.



Figure 8. Control tomography.

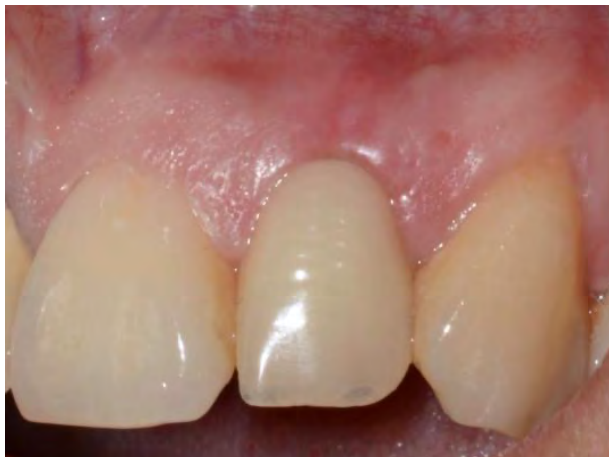

Figure 9. Soft tissue and hard tissue stability and recovery.

DISCUSSION

Dental implant therapy has progressed to incorporate procedures involving soft tissue grafting, which are increasingly favored due to their capacity to enhance biological, functional, and aesthetic outcomes (9). These periodontal plastic surgical procedures are vital in creating a health-promoting environment (10). Despite some debate in scientific literature about the necessity for increased keratinized tissue width or mucosal thickness at implant sites, evidence indicates that these procedures can significantly contribute to peri-implant health (11).

Conversely, implants that are immediately loaded post-extraction have set a benchmark in dental restoration, providing a swift and efficient solution for rehabilitation following tooth loss. The amalgamation of this technique with guided bone regeneration using connective grafts has surfaced as a comprehensive strategy that tackles the issues of tooth loss, promising enduring and satisfactory results for patients (12). Placing an implant immediately after tooth extraction aids in preserving the bone and gingival architecture, which is essential for the aesthetic and functional success of the implant. However, this technique necessitates primary implant stability and meticulous management of gingival recession to prevent long-term complications (13).

When guided bone regeneration is employed alongside connective tissue grafting, it enhances the quality of the soft tissue surrounding the implant, leading to improved integration. This combination of techniques provides a comprehensive solution that caters to both the need for immediate function and long-term aesthetics (14). The integration of immediate-loaded post extraction implants with connective graft-guided bone regeneration signifies an advanced approach in contemporary dentistry. While it promises superior outcomes, it is crucial for practitioners to conduct

detailed planning and adhere to strict protocols to ensure the success of the treatment (15).

Free gingival grafting (FGGT), which consists of soft tissue harvested from the palate along with the overlying epithelium, has become established as a technique for retrieving or augmenting missing keratinized tissue. This methodology was pioneer in its application for this purpose. The findings of various investigations have evidenced a reduction in the dimension of the graft materials after their placement, although they stand out for their efficacy in extending the extension of the keratinized tissue. However, this technique can lead to increased morbidity during the surgical procedure, as well as differences in the shade of the grafted tissue compared to adjacent tissues (16).

Evidence strongly supports the use of autologous soft tissue grafts in surgical and peri-implant procedures to optimize both tissue health and appearance. The free gingival grafting technique is widely recognized for its efficacy in increasing soft tissue thickness around teeth and implants. However, connective tissue grafts stand out for their high predictability in achieving complete coverage of tooth roots or areas of tissue dehiscence, thus contributing to superior esthetics. Both adequate tissue thickness and the presence of keratinized tissue are considered key elements in maintaining optimal peri-implant health and promoting soft tissue augmentation in the implant environment (17).

Finally, it is important to consider some restrictions in procedures such as immediate post-extraction dental implant placement and bone regeneration with the aid of connective tissue grafts. These processes require detailed patient selection based on the condition and amount of remaining bone. In addition, there is the risk of mucosal recession around the implant and the challenge of achieving adequate soft tissue contouring. These factors are crucial to the proper integration of the

implant to the bone and its final esthetic appearance, making a thorough evaluation essential to ensure the long-term success of the treatment.

CONCLUSION

This report emphasizes the significance of a multidisciplinary approach and the use of innovative techniques in the management of dental fracture cases with periapical lesions. Post-extraction implant placement and guided bone regeneration, along with meticulous attention to detail, proved to be a viable option for achieving satisfactory clinical and esthetic results.

AUTHOR CONTRIBUTION STATEMENT

Study conception: I.C., D.A.T., F.M.T. and R.M.

Data collection: I.C. and D.A.T.

Data acquisition and analysis: F.M.T. and F.M.

Data interpretation: F.M., R.M., I.C., D.A.T. and F.M.T.

Manuscript writing: F.M.T., F.E.C., F.M., R.M. and I.C.

PATIENT DECLARATION OF CONSENT

The authors affirm that they have secured all necessary consent forms from the patients. In these forms, the patients have granted permission for their images and other clinical data to be included in the journal. The patients are aware that while their names and initials will not be disclosed, and every effort will be made to protect their identity, absolute anonymity cannot be assured.

ACKNOWLEDGEMENTS

The authors wish to thank the Universidad San Ignacio de Loyola for all their unconditional support for preparing this case report.

REFERENCES

1. Jayesh R.S., Dhinakarsamy V. Osseointegration. *J Pharm Bioallied Sci.* 2015; 7 (1): S226-9.
2. Ahamed M.S., Mundada B.P., Paul P., Reche A. Partial Extraction Therapy for Implant Placement: A Newer Approach in Implantology Practice. *Cureus.* 2022; 14 (11): e31414.
3. Cha H.S., Kim J.W., Hwang J.H., Ahn K.M. Frequency of bone graft in implant surgery. *Maxillofac Plast Reconstr Surg.* 2016; 38 (1): 19.
4. Zhao R., Yang R., Cooper P.R., Khurshid Z., Shavandi A., Ratnayake J. Bone Grafts and Substitutes in Dentistry: A Review of Current Trends and Developments. *Molecules.* 2021; 26 (10): 3007.
5. Haugen H.J., Lyngstadaas S.P., Rossi F., Perale G. Bone grafts: which is the ideal biomaterial? *J Clin Periodontol.* 2019; 46 Suppl 21: 92-102.
6. Girón J., Kerstner E., Medeiros T., Oliveira L., Machado G.M., Malfatti C.F., Pranke P. Biomaterials for bone regeneration: an orthopedic and dentistry overview. *Braz J Med Biol Res.* 2021; 54 (9): e11055.
7. Solakoglu Ö., Heydecke G., Amiri N., Anitua E. The use of plasma rich in growth factors (PRGF) in guided tissue regeneration and guided bone regeneration. A review of histological, immunohistochemical, histomorphometrical, radiological and clinical results in humans. *Ann Anat.* 2020; 231: 151528.
8. Kang M., Huang C.C., Lu Y., Shirazi S., Gajendrareddy P., Ravindran S., Cooper L.F. Bone regeneration is mediated by macrophage extracellular vesicles. *Bone.* 2020; 141: 115627.

9. Thoma D.S., Buranawat B., Hämmerle C.H., Held U., Jung R.E. Efficacy of soft tissue augmentation around dental implants and in partially edentulous areas: a systematic review. *J Clin Periodontol.* 2014; 41 Suppl 15: S77-91.
10. Rocuzzo M., Grasso G., Dalmaso P. Keratinized mucosa around implants in partially edentulous posterior mandible: 10-year results of a prospective comparative study. *Clin Oral Implants Res.* 2016 ; 27 (4): 491-6.
11. Thoma D.S., Naenni N., Figuero E., Hämmerle C.H.F., Schwarz F., Jung R.E., Sanz-Sánchez I. Effects of soft tissue augmentation procedures on peri-implant health or disease: A systematic review and meta-analysis. *Clin Oral Implants Res.* 2018; 29 Suppl 15: 32-49.
12. Buyukozdemir Askin S., Berker E., Akinci-bay H., Uysal S., Erman B., Tezcan İ., Karabulut E. Necessity of keratinized tissues for dental implants: a clinical, immunological, and radiographic study. *Clin Implant Dent Relat Res.* 2015; 17 (1): 1-12.
13. Tani C., Carli L., Vagnani S., Talarico R., Baldini C., Mosca M., Bombardieri S. The diagnosis and classification of mixed connective tissue disease. *J Autoimmun.* 2014; 48-49: 46-9.
14. Gunnarsson R., El-Hage F., Aaløkken T.M., Reiseter S., Lund M.B., Garen T.; Norwegian MCTD study group; Molberg Ø. Associations between anti-Ro52 antibodies and lung fibrosis in mixed connective tissue disease. *Rheumatology (Oxford).* 2016; 55 (1): 103-8.
15. Zucchelli G., Tavelli L., McGuire M.K., Rasperini G., Feinberg S.E., Wang H.L., Giannobile W.V. Autogenous soft tissue grafting for periodontal and peri-implant plastic surgical reconstruction. *J Periodontol.* 2020; 91 (1): 9-16.
16. de Resende D.R.B., Greggi S.L.A., Siqueira A.F., Benfatti C.A.M., Damante C.A., Raghianti Zangrando M.S. Acellular dermal matrix allograft versus free gingival graft: a histological evaluation and split-mouth randomized clinical trial. *Clin Oral Investig.* 2019; 23 (2): 539-550.
17. Lim H.C., An S.C., Lee D.W. A retrospective comparison of three modalities for vestibuloplasty in the posterior mandible: apically positioned flap only vs. free gingival graft vs. collagen matrix. *Clin Oral Investig.* 2018; 22 (5): 2121-2128.