



Congenital Shunts of the Portal Venous System: Case-series of Uncommon Shunts

Liliana Santos,* Susana Nobre,** Nadia Laezza,* Catarina Cunha,*^{***} Isabel Gonçalves,** Maria F. Lopes*^{**,***}

* Department of Pediatric Surgery, Centro Hospitalar e Universitário de Coimbra, Coimbra, Portugal.

** Pediatric and Adult Liver Transplantation Unit, Centro Hospitalar e Universitário de Coimbra, Coimbra, Portugal.

*** Faculty of Medicine of the University of Coimbra, Coimbra, Portugal.

ABSTRACT

Background and aims. Congenital shunts of the portal venous system are rare entities that can present in children with clinical heterogeneity. To evaluate the clinical course of children with uncommon shunts presenting to our institution and examine the available literature on this topic. Medical records of children with rare forms of congenital shunts were retrospectively reviewed for demographics, symptoms, management, and outcome between 2003 and 2016. **Results.** Three female patients with congenital shunts, including a congenital mesenterico-portal Rex shunt (n = 1) and congenital portosystemic shunts (CPSS) (n = 2), were referred for surgical evaluation between ages 4 and 9. Median follow-up was 8 years (range, 6-13 years). One asymptomatic patient did not require treatment and remained disease-free during long-term follow-up. The other 2 patients with CPSS and unusual symptoms, including liver focal nodular hyperplasia (FNH) in infancy (n = 1) and bleeding from esophageal varices (n = 1), showed subsequent progression to liver nodules that were managed by endovascular shunt occlusion. One patient showed symptom resolution and the other showed stable lesions at last follow-up. Literature yielded descriptions of two cases of congenital mesenterico-portal Rex shunt, one case of coincident CPSS and FNH in infancy, but zero reports of bleeding from esophageal varices. **Conclusions.** This case series examines each distinct patient's presentation, discusses the diagnosis, management and outcome and compares findings while discussing literature on this topic. A high index of suspicion and familiarity with unusual forms and treatment options is required to allow timely diagnosis and appropriate treatment.

Key words. Congenital portosystemic shunt. Congenital mesenterico-portal Rex shunt. Portal venous system. Rex shunt. Pediatrics.

INTRODUCTION

The portal venous system, whose fetal architecture evolves through a complex process of the vitelline venous system between the 4th and the 12th weeks of gestation, carries blood from the abdominal portion of the digestive system, spleen, pancreas, and gallbladder to the liver.¹⁻³ This system typically consists of the portal vein, which is formed by the junction of the splenic and superior mesenteric veins, and several levels of portal venous branches.¹ Ligamentum teres (or round ligament) and *ligamentum venosum* represent fibrous remnants of parts of vitelline veins. The first is the obliterated remnant of the left umbilical vein, which usually joins the left branch of the portal vein. The second corresponds to the fetal drainage pathway for flow diverted from the umbilical vein to the

inferior vena cava via the ductus venosus. In fetal life, the ductus venosus diverts a portion of the blood flow from the left umbilical vein directly to the inferior vena cava.² An aberrant development of the portal vein or vena cava in early embryonic life explains the genesis of congenital portosystemic shunts (CPSS).³

Congenital portal venous shunts may present as physiological variants of the normal anatomy or, as in CPSS, may involve diversion of portal venous blood into the systemic venous circulation, thus bypassing the liver and altering the normal flow dynamics with consequent morbidity.^{2,3}

CPSS, also known as Abernethy malformations,³ are rare vascular malformations of the portal venous system with an estimated incidence of 1 per 25,000 to 1 per 30,000 live births.^{4,5} A recently described classification categorizes them into two types: type I shunt is characterized by

Table 1. Classification of congenital portosystemic shunts.

Type	Description
I*	No intrahepatic portal flow (congenital absence of PV or type I Abernethymalformation).
Ia	The splenic vein and superior mesenteric vein join the inferior vena cava separately.
Ib	The splenic vein and superior mesenteric vein join the inferior vena cava as a confluence.
II**	Partial shunt with preserved hepatic flow (type II Abernethy malformation).
IIa	Arising from left or right PV (includes PDV).
IIb	Arising from main PV (including its bifurcation or splenomesenteric confluence).
IIc	Arising from the mesenteric, gastric or splenic veins.

* According to Morgan and Superina.⁶ ** According to Lautz, et al.⁷ **PV:** Portal vein. **PDV:** Patent ductus venosus.

complete shunting and absence of a portal vein, while type II exhibits partial shunting and a hypoplastic portal vein (Table 1).^{6,7}

CPSS are usually diagnosed in children but may be discovered at any age. These typically occur in the absence of underlying cirrhosis. The clinical manifestations can range from entirely asymptomatic patients to hepatic or systemic sequelae of portosystemic shunting. Neonates can present with cholestatic jaundice. Hepatic encephalopathy, hepatopulmonary syndrome, several metabolic derangements of the liver and the development of benign and malignant liver tumors are clinical manifestations commonly found in older children.^{3,5,8,9} CPSS can also present with unusual symptoms and, in such cases, the diagnosis may be difficult. However, the vascular malformations and their complications are now accurately diagnosed by the use of imaging studies, including abdominal ultrasound (US), computerized tomography (CT) and magnetic resonance imaging.³

While a physiological variant of the portal venous system only requires surveillance, CPSS treatment options include conservative management, endovascular shunt occlusion or operative ligation.^{5,7} Shunt closure in two-steps or liver transplantation may be required for type I shunts with severe portal venous hypoplasia.¹⁰

This study presents three rare cases of portal venous shunts including a congenital mesenterico-portal Rex shunt and 2 cases of type II CPSS that presented with unusual symptoms and reviews the available literature on this topic. Because the literature only provides a few cases with these clinical scenarios, our goal is to examine each distinct patient's clinical presentation, discuss the diagnosis, management, and outcome, and compare the findings while discussing the literature on this topic.

MATERIALS AND METHODS

This retrospective study was conducted in strict accordance with confidentiality recommendations approved by our health system's institution.

Patients with congenital portal venous shunts were identified from the retrospective review of a prospective database maintained at our tertiary university pediatric hospital (Hospital Pediátrico-Centro Hospitalar e Universitário de Coimbra, Portugal), between January 2003 and January 2016.

Eligible cases were defined as those that met the following criteria: patients with uncommon forms of portal venous shunts, aged less than 18 yr, and who had more than 5 years clinical follow-up.

Patient's medical records were reviewed for demographic information, clinical presentation, laboratory data and imaging, management and outcome.

Uncommon type of CPSS was defined as less than 5 cases reported in the literature.

A search of similar reports in medical literature was conducted on Medline (via Pubmed) using the following search terms: 'congenital meso-Rex shunt'; 'congenital mesenterico-portal shunt'; 'congenital portosystemic shunt'; 'congenital intrahepatic shunt'; 'congenital portohepatic shunt'; 'congenital portocaval shunt'; 'liver tumor'; 'focal nodular hyperplasia'; 'gastrointestinal bleeding'. The Boolean operators 'AND' and 'OR' were used to combine and narrow the searches. All identified cases were reviewed and the findings were summarized.

The portosystemic shunts were categorized according to a classification system adapted from other studies (Table 1).^{6,7}

RESULTS

Patient demographics, clinical characteristics, management, and outcome

Anatomy and categorization of the vascular shunts, management, outcome and follow-up are summarized in table 2 and the schematic anatomy of the congenital venous shunts are shown in figure 1. The subjects are presented as Case 1, Case 2 and Case 3.

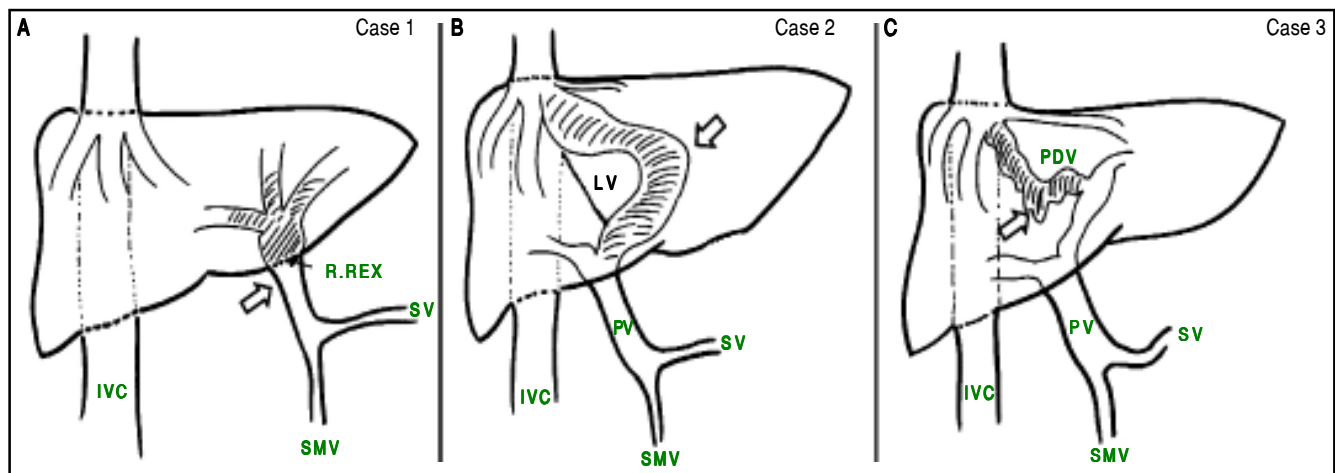


Figure 1. Schematic anatomy of the shunts (white arrows) in: **A.** Case 1-Congenital mesenterico-portal Rex shunt. **B.** Case 2- Type II portosystemic shunt (congenital intrahepatic portocaval shunt). **C.** Case 3- Type II portosystemic shunt (PDV). IVC: Inferior vena cava. R: Recessus. SV: Splenic vein. SMV: Superior mesenteric vein. LV: Ligamentum venosum. PV: Portal vein.

Because there is currently no established classification for the malformation of case 1, the classification system used for the categorization of shunts (Table 1) was applied only to cases 2 and 3.

The patient demographics described in this cohort included 3 females with unusual types of portal venous shunts, including congenital mesenterico-portal shunt (n = 1) and congenital portosystemic shunts (CPSS) (n = 2). The patients were referred for surgical evaluation at our institution between ages 4 and 9 years. Clinical manifestations included incidental finding (n = 1), a rare type of liver tumor in infancy (n = 1) and severe gastrointestinal bleeding (n = 1) that progressed to multiple liver nodules during adolescence. The diagnosis was established by imaging. Median follow-up was 8 years (range, 6-13 years). One asymptomatic patient did not require surgical management and remained disease-free during long-term follow-up. The other 2 patients with CPSS and liver nodules were managed by endovascular shunt occlusion. At last follow-up, one patient showed symptom resolution and the other showed stable lesions.

Case summaries

- **Case 1.** Congenital mesenterico-portal Rex shunt. A 4-year-old asymptomatic girl was found to have an incidental “portal venous system variant” on abdominal ultrasound (US) during a urinary tract infection workup. Initial US-Doppler evaluation of the abdomen showed the absence of the main portal vein and an anomalous abdominal vein between the splenomesenteric confluence and the left liver, at the Rex recessus, where it was seen to split into several intrahepatic venous branches. A normal hepatopetal

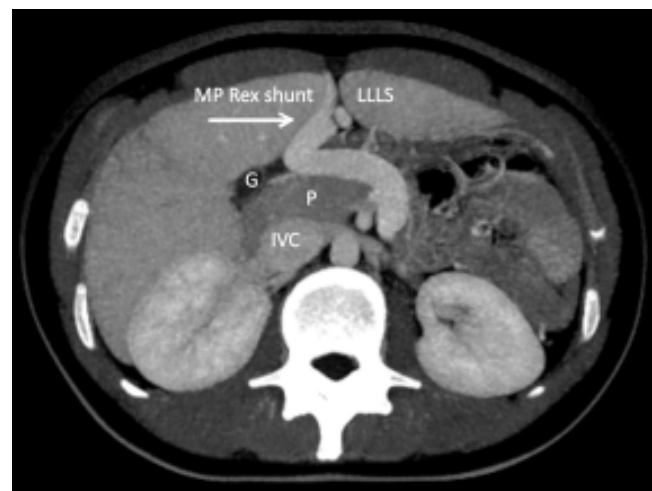


Figure 2. CT angiography of case 1 shows a congenital mesenterico-portal (MP) Rex shunt (arrow). LLLS: Liver's left lateral segment. G: Gallbladder. P: Pancreas. IVC: Inferior vena cava.

flow with normal velocity, a normal liver, and polysplenia were also observed. The patient's complete blood count, coagulation screen and serum chemistry panel, including ammonia concentration and liver function tests, were within normal limits. A subsequent CT angiography of the abdomen (Figure 2) was performed and the patient was diagnosed with congenital mesenterico-portal Rex shunt with polysplenia and heterotaxia. Echocardiogram showed a ventricular septal defect. Surveillance US of the abdomen was performed annually to monitor progression to disease. The patient still attends follow-up examinations 13 years after the diagnosis. On her last recent follow-up, she remained asymptomatic.

- Case 2.** Type II portosystemic shunt (congenital intrahepatic portocaval shunt) with focal nodular hyperplasia (FNH) of the liver presenting at the age 1 yr. A 12-year-old girl presented to our pediatric liver transplant unit with multiple liver nodules. The patient was diagnosed with left liver mass (FNH) during her infancy and was treated with left segmentectomy at the age of 1 yr. On subsequent follow-up, two new liver tumors were detected prior to admission to our hospital. Her serum chemistry panel, including ammonia concentration and liver function tests, were within normal limits. Initial imaging studies at our hospital showed at least 5 ill-defined hepatic lesions, with different range size (maximum 2.8 cm) and unusual imaging which raised the suspicion of FNH. CT angiography of the chest and abdomen also showed a direct intrahepatic portocaval shunt, arising from the left portal vein and diverting the blood to the inferior vena cava at the right atrium, and no observable portal flow to the liver (Figure 3). The echocardiogram was normal. The patient then underwent an endovascular occlusion of the shunt using an Amplatzer vascular plug. At 20 months follow-up post-procedure, a CT scan showed an occluded shunt, expansion of the intrahepatic portal vein system and near-complete regression of liver lesions. The patient is currently in good health (after 6 years of shunt occlusion), but she is no longer followed at our clinic.
- Case 3.** Type II portosystemic shunt (patent ductus venosus-PDV) with bleeding from esophageal varices. A 9-year-old girl with a prior 8-year history of idiopathic splenomegaly and thrombocytopenia presented to our emergency department with esophageal variceal bleeding. Vital signs revealed hypotension. Laboratory findings were significant for anemia (hemoglobin: 4.7 g/dL) and thrombocytopenia (platelet count: $66 \times 10^9/L$). There was no previous history of gastrointestinal bleeding. Before admission, the platelet counts ranged from $36 \times 10^9/L$ to $87 \times 10^9/L$, liver tests were normal and several US-Doppler examinations were found to be negative for portal cavernous transformation. After admission, an emergent upper endoscopy revealed grade 3 esophageal varices that were not actively bleeding at that time. Esophageal varices were successfully treated by endoscopic band ligation. The abdominal US showed portal vein obstruction with cavernous transformation and a 13.3 cm spleen. CT scan revealed a PDV, 17 mm in diameter, which diverted the portal vein blood to the inferior vena cava (Figure 4) and severe intrahepatic cavernous transformation. At subsequent endovascular intervention, aiming ductus venosus occlusion, the shunt occlusion test did not reveal any observable intrahepatic portal ve-

nous flow. The echocardiogram was normal with no evidence of pulmonary hypertension.

Two liver nodules were discovered on US at the age 13 yr. Serum alpha-fetoprotein values were within normal limits; magnetic resonance imaging suggested hepatic nodular regenerative lesions; the histopathological examination of a liver sample without nodules, obtained by US-guided percutaneous biopsy, found no cirrhosis and unexpectedly revealed areas of enlarged and herni-

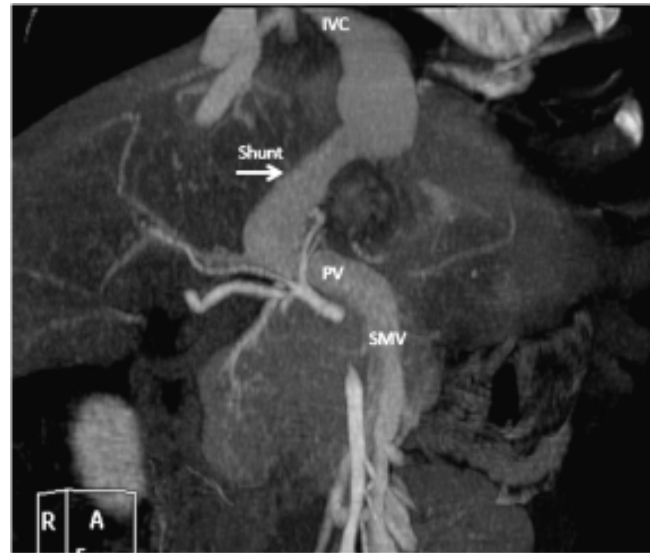


Figure 3. CT angiography of case 2 shows a congenital portosystemic shunt (arrow) arising from the left portal vein and diverting the flow to the inferior vena cava/right atrium. IVC: Inferior vena cava. PV: Portal vein. SMV: Superior mesenteric vein.

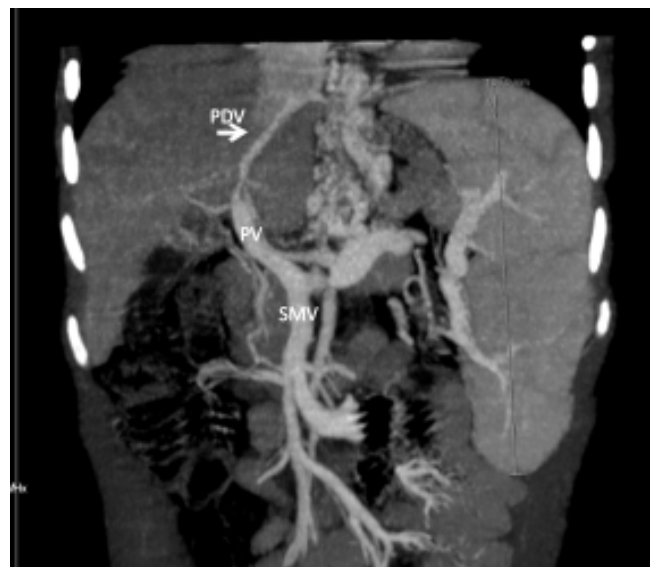

Figure 4. CT angiography of case 3 shows a patent ductus venosus (PDV) (arrow). PV: Portal vein. SMV: Superior mesenteric vein.

ated portal veins, small portal tracts with attenuated portal vein radicals and sinusoidal dilatation.

Due to increasing size of liver nodules (maximum 7.9 cm), the patient underwent shunt occlusion at the age 15 yr, which was successfully achieved by endovascular intervention using a vena cava filter device. The patient's post-procedure course was uneventful. At the time of her last post-procedure visit (36-month follow-up) the patient remained well, did not have any recurrent bleeding, and her hepatic lesions remained stable (maximum 6.9 cm). At this time, laboratory studies revealed hypersplenism, with platelet count less than $50 \times 10^9/L$, and serum alpha-fetoprotein value was within normal limits; US assessment of the spleen showed splenomegaly (20 cm); and endoscopy to look for varices was negative. The patient continues in close surveillance.

DISCUSSION

Uncommon varieties of congenital portal venous shunts are exceedingly rare congenital entities which have not been well published in the literature. For the current review, we focus on the uncommon forms of portal venous shunts. This study describes three challenging cases of portal venous shunts. We highlight one case with an extremely rare physiological variant of the portal venous system and two cases with unusual manifestations of CPSS.

Several shunt types of the hepatic vascular venous system have been described in the medical literature, mostly limited to case reports and small case series, confirming the rarity of these abnormalities.¹¹ While CPSS usually presents with a spectrum of clinical symptoms, anatomic and physiological variants of the normal vascular anatomy can be incidentally detected and usually remain asymptomatic. CPSS clinical characteristics may include features related to portal blood shunting such as hepatopulmonary syndrome, metabolic dysfunction, and hepatic encephalopathy.³ CPSS may also present features related to associated congenital anomalies, including cardiac, venous, arterial, skeletal, visceral abnormalities, biliary atresia,³ and heterotaxia and polysplenia syndrome.¹² The presence of liver tumors has been reported in association with CPSS. FNH, nodular regenerative hyperplasia, hepatic adenoma, hepatoblastoma and hepatocellular carcinoma are the usual histological findings.³

Since the first Abernethy malformation that was described by John Abernethy in 1793 upon autopsy of a deceased 10-month-old female,¹³ traditional classifications categorized CPSS into two broad types: intra- and extrahepatic. The first included the abnormal intrahepatic connections between a branch of the portal vein and hepatic

veins or the inferior vena cava (including the PDV) and the second included the shunts that arose from the main portal vein to the inferior vena cava.^{11,14-15}

In 1994, Morgan and Superina⁶ introduced a classification system based on whether the portal vein, often hypoplastic, was present, and whether the liver was perfused with blood from the mesenteric venous system. In a type I shunt, there was a complete end-to-side portocaval fistula with no observable portal flow to the liver. Type I shunt was further subcategorized into type Ia, in which the splenic vein and superior mesenteric vein join the inferior vena cava separately, or type Ib, in which they join the inferior vena cava as a confluence.⁶ In a type II shunt, the liver was partially perfused with portal blood. Type II shunts were further subcategorized into type IIa, type IIb and type IIc by Lautz et al in 2011.⁷ A shunt arising from a branch of the portal vein was classified as type IIa. This includes the PDV, which connects the left portal vein to the left hepatic vein near its entry into the inferior vena cava. Shunts arising from the main portal vein or its bifurcation were classified as type IIb, whereas those arising from the mesenteric, gastric, or splenic veins were classified as type IIc.⁷ Type II shunts in the Lautz, *et al.*⁷ classification are frequently mentioned in literature as intrahepatic shunts.^{11,14,15}

The phenotype of our case 1 (Table 2), with a physiological variant of the portal venous system, was similar to that of a well-known surgical technique first described by de Ville de Goyet in 1999,¹⁶ the Meso-Rex bypass shunt, also known as mesenteric to left portal vein bypass or, the Rex shunt. This operation is currently the preferred treatment for extrahepatic portal vein obstruction in the pediatric and adolescent population.^{17,18} By creating a conduit between the mesenteric system and the left portal vein, this surgical shunt reestablishes physiological hepatopetal flow. As in the surgical shunt, the malformation in case 1 brings the splanchnic blood flow into the liver in a hepatopetal fashion.

To our knowledge, phenotypes of a physiological variant of the portal venous system, analogous to our case 1, have been described only twice in the literature. Table 3 compares our patient to the two patients from literature. A congenital mesenterico-portal shunt was first described in a 2-day-old boy during an operation for exomphalos, in whom the native umbilical vein had acquired mesenteric venous outflow to bypass an in-utero portal vein obstruction (Table 3).¹⁹ The second case in the literature was found during a Kasai operation for biliary atresia in a 45-day-old girl (Table 3).²⁰ This child showed an abnormal venous tract crossing freely over the gastric antrum, originating from the superior mesenteric vein and draining into the distal portion of the umbilical vein and the Rex recessus; this was associated with the absence of the

Table 2. Patient demographics, clinical symptoms, shunt anatomy, management, and outcome of 3 children with a congenital portal venous shunt.

Case	Age (yr)* / Gender	Symptoms*	Anatomy/shunt classification	Intervention	Follow-up (yr)	Status at last follow-up
1	4/F	No symptoms	Splenomesenteric confluence to intrahepatic left portal vein	None	13	In good health
2	12/F	Liver nodules	Type IIa CPSS (left PV to IVC/RA)	Endovascular occlusion	6	Symptom resolution
3	9/F	Variceal bleeding	Type IIa CPSS (PDV)	Endovascular occlusion	8	Liver nodules, EHPVO

* Age (years) at referral. **F:** Female. **PV:** Portal vein. **CPSS:** Congenital portosystemic shunt. **IVC/RA:** Inferior vena cava/right atrium. **PDV:** Patent ductus venosus. **EHPVO:** Extrahepatic portal vein obstruction.

Table 3. A comparison between our patient, with congenital mesenterico-portal Rex shunt, and the patients from the literature.

Study	Age at diagnosis/Gender	Diagnosis+ Other anomalies	Anatomy	Follow-up	Outcome
Current article	4-yr-old/ F	Incidental finding Cardiac (VSD). Polysplenia syndrome	PV absence. Shunt (SMV to the Rex recessus).	13 years	No symptoms
Rahman <i>et al.</i> ¹⁹	2-day-old/ M	At laparotomy (exomphalos)	PV obstruction. Shunt (SMV confluence to the Rex recessus).	N/A	N/A
Grimaldi <i>et al.</i> ²⁰	45-day-old/F	At laparotomy (Kasai for BA) Polysplenia syndrome.	PV absence. Shunt (SMV confluence to the distal portion of the umbilical vein and the Rex recessus).	N/A	N/A

F: Female. M: Male. VSD: Ventricular septal defect. BA: Biliary atresia. PV: Portal vein. SMV: Superior mesenteric vein. N/A: Not available.

portal vein in its usual site and polysplenia syndrome. Our case 1 (Tables 2 and 3) is unique because of a long-term follow-up; the patient remained disease-free over the past 13 years of clinical surveillance.

Regarding CPSS, demographics, and clinical manifestations have been well described in the medical literature. In a recent literature review, Sokollic, *et al.*⁹ reported 316 patients; of these, 177 were male, 185 had an extrahepatic and 131 an intrahepatic CPSS. The age at diagnosis ranged from prenatal to 84 years; 66% of the patients were diagnosed under the age 12 years and 24% in adulthood. Cardiac anomalies were found in 22% of patients. The main complications were hyperammonemia/neurological abnormalities (35%), liver tumors (26%), and pulmonary hypertension or hepatopulmonary syndrome (18%).

Although many shunts can lead to complications, namely hyperammonemia/neurological abnormalities, and pulmonary hypertension or hepatopulmonary syndrome,⁹ none of the 2 patients with CPSS we report on here experienced any of these symptoms. Of note, none of our patients had evidence of hyperammonemia on laboratory studies throughout their long-term follow-up. Why hyperammonemia was not a more consistent finding in our patients with CPSS is a matter of speculation. Modification of the gut bacterial profile has been proposed as a reason for the absence of hyperammonemia.²¹

With respect to unusual symptoms presented by both our cases with a CPSS, liver tumor diagnosed as FNH in infants (case 2) is an uncommon event;²² moreover its as-

sociation with congenital portocaval shunt has previously been reported only three times in the literature.²³

Benign liver tumors, namely regenerative nodular hyperplasia and FNH, have been described in the literature in association with CPSS. The pathogenesis remains unclear but flow deprivation of the liver has been implicated as a predisposing factor.²²

FNH, a non-specific benign hyperplastic reaction to vascular abnormalities, is extremely rare during childhood, accounting for 2% to 7% of all pediatric liver tumors.²² First known as an incidental lesion, FNH can be associated with CPSS.²² Interestingly, FNH was by far the most common tumor in a retrospectively evaluated small case series of CPSS associated with liver tumors. Six of 8 patients who had CPSS and liver tumors had FNH and this was diagnosed during the second and third decades of life.²⁴ As in our case 2, this tumor is more frequent in females. It is usually diagnosed after the age of 8 yr,^{22,24} rather than earlier, as seen in our patient and in another child reported in the literature,²⁵ in whom clinical symptoms occurred at the age 1 yr. The diagnosis of FNH in children can be challenging because uncharacteristic lesions on imaging occur in two-thirds of cases.^{22,26} Typical signs on imaging are arterial hyper-enhancing lesions, characteristically with a central T2-W hyperintense scar.²⁷ This liver lesion is typically considered a benign process. However, in 2012, there was one case report describing the progression of an FNH to a malignant tumor in a patient with Abernethy malformation.²⁸ Therefore, it is important to recognize that focal liver lesions in children, especially FNH and nodular regenerative hyperplasia, can be a warning sign of a CPSS and that curative management options can be given.

Regarding our case 3, contrary to lower gastrointestinal bleeding originating from rectal varices in CPSS,²⁹ upper gastrointestinal bleeding from esophageal varices rupture was not found in the literature. Two case reports described gastrointestinal bleeding associated with a PDV from other causes. Alomary, *et al.*³⁰ reported on a six-year-old boy with a large PDV and massive gastrointestinal bleeding, however, the authors proposed that relative ischemia of the bowel rather than portal hypertension was the cause of the bleeding in this child. Nagano, *et al.*³¹ reported on a 29-year-old man with a PDV and gastrointestinal bleeding caused by gastric ulcers.

The portal cavernous transformation was documented in our case 3 at the time of esophageal variceal bleeding and it was shown its coexistence with a PDV. PDV is a rare anomaly, more common in boys. This condition is reported to occur mostly in adults with portal hypertension caused by cirrhosis and portal vein thrombosis.³² Some authors have speculated that the persistent patency of the ductus venosus may be a cause rather than a manifes-

tation of the cirrhosis and portal hypertension.³³⁻³⁴ PDV with extrahepatic portal vein obstruction without cirrhosis is not a feature in children; therefore, a high index of suspicion is necessary for children who have that association.

We assume that the PDV in patient 3 was congenital rather than acquired. The progressive increase in vascular resistance to blood flow through a hypoplastic portal vein, associated with a small diameter of the PDV, led to portal hypertension.

Our hypothesis of coexistent congenital PDV was supported by signs of portal hypertension without portal vein cavernous transformation shown by US during the earlier course of the illness, even though it is known that US imaging can fail the diagnosis of absent or hypoplastic intrahepatic portal veins, a feature which is better detected by CT and magnetic resonance imaging.³⁵

At present, we know that some CPSS may regress spontaneously before the age 2 yr and other shunts may remain asymptomatic for long periods of time.^{4,9,36} Closure of a CPSS persisting after 2 years old is recommended for all patients especially in view of the serious long-term complications.^{8,14} Most type II shunts can be managed by operative ligation, or by endovascular occlusion⁷ with careful monitoring for the development of portal hypertension.¹⁴ Transcatheter embolization has been considered safer and less invasive than surgery and is particularly important in the setting of coexistent cirrhosis and portal hypertension, where preservation of hepatic parenchyma is important. While liver resection of a benign mass arising as a portosystemic shunt complication is generally not required, since this tend to disappear after shunt ligation, retrospectively this surgery could have been avoided in our patient 2.

Both surgical or transcatheter interventions must be preceded by a tolerance test to shunt occlusion, by monitoring portal pressure in response to the transitory shunt occlusion; a high portal pressure during this test may advise a two-stage approach. This latter approach is related to the risk of an acute rise in the portal pressure, in cases of severe hypoplasia or absence of portal vein that cannot accommodate the flow overload.¹⁴

Effective interventional radiological methods using coils, plugs, and/or stents for shunt occlusion have proven successful for the management of type II CPSS shunts, including PDV.⁷ Cases 2 and 3 of the present study underwent endovascular shunt occlusion, with a plug and a stent, respectively, without major complications. Because patient 3 did present unconvincing intrahepatic circulation during the shunt occlusion test, an endovascular device that allowed partial blood flow through the shunt was placed. In spite of a high risk of acute portal hypertension, the procedure was performed without complications. Our

view is that protection from this serious adverse event was given by a matured portal cavernous that accommodated increased hepatopetal blood flow and pressure.

Taken together, our study is unique in reporting three challenging uncommon cases, including one case of a congenital mesenterico-portal Rex shunt and two cases of type II CPSS. The first case was an incidental finding of an asymptomatic congenital shunt, with a 13 years follow-up without evidence of complications. The second and third cases (with a type II CPSS) showed initial infrequent symptoms (liver tumor in a 1-year-old girl and bleeding from esophageal varices in a 9-year-old girl). Both cases showed later progression to multiple liver nodules, which is a well known major complication of CPSS. For this reason, the patients underwent shunt occlusion, which was followed by regression of the liver lesions in one case and stabilization in the other.

A literature review revealed two other published cases of a congenital mesenterico-portal Rex shunt, one case of FNH of the liver in a 1-year-old girl with a CPSS, but zero reports of bleeding from esophageal varices.

CONCLUSIONS

We highlight the rarity of uncommon forms of congenital portal venous shunts with three additional cases from our institution adding to the paucity of literature on the subject. All three patients in this series have benefited from an appropriate management at our referral tertiary center. Given that congenital portal venous shunts are usually managed in large referral centers and that rare conditions are largely misdiagnosed initially owing to diagnostic unfamiliarity, dissemination of information from referral tertiary centers will continue to be valuable in facilitating correct diagnosis and categorization to guide further management decisions. Timely diagnosis and correct categorization are essential because treatment options for various subtypes of shunts are significantly different.

ABBREVIATIONS

- **CPSS:** congenital portosystemic shunts.
- **CT:** computerized tomography.
- **FNH:** focal nodular hyperplasia.
- **PDV:** patent ductus venosus.
- **US:** ultrasound.

REFERENCES

1. Lee WK, Chang SD, Duddalwar VA, Comin JM, Perera W, Lau WF, Bekhit EK, et al. Imaging assessment of congenital and acquired abnormalities of the portal venous system. *Radiographics* 2011; 31: 905-26.
2. Leite AF, Mota A Jr, Chagas-Neto FA, Teixeira SR, Elias Junior J, Muglia VF. Acquired portosystemic collaterals: anatomy and imaging. *Radiol Bras* 2016; 49: 251-6.
3. Ghuman SS, Gupta S, Buxi TB, Rawat KS, Yadav A, Mehta N, Sud S. The Abernethy malformation-myriad imaging manifestations of a single entity. *Indian J Radiol Imaging* 2016; 26: 364-72.
4. Paganelli M, Lipsich JE, Sciveres M, Alvarez F. Predisposing Factors for Spontaneous Closure of Congenital Portosystemic Shunts. *J Pediatr* 2015; 167: 931-5.
5. Bernard O, Franchi-Abella S, Branchereau S, Pariente D, Gauthier F, Jacquemin E. Congenital portosystemic shunts in children: recognition, evaluation, and management. *Semin Liver Dis* 2012; 32: 273-87.
6. Morgan G, Superina R. Congenital absence of the portal vein: two cases and a proposed classification system for portosystemic vascular anomalies. *J Pediatr Surg* 1994; 29: 1239-41.
7. Lautz TB, Tantemsapya N, Rowell E, Superina RA. Management and classification of type II congenital portosystemic shunts. *J Pediatr Surg* 2011; 46: 308-14.
8. Franchi-Abella S, Branchereau S, Lambert V, Fabre M, Steimberg C, Losay J, Riou JY, et al. Complications of congenital portosystemic shunts in children: therapeutic options and outcomes. *J Pediatr Gastroenterol Nutr* 2010; 51: 322-30.
9. Sokollik C, Bandsma RH, Gana JC, van den Heuvel M, Ling SC. Congenital portosystemic shunt: characterization of a multisystem disease. *J Pediatr Gastroenterol Nutr* 2013; 56: 675-81.
10. Kanazawa H, Nosaka S, Miyazaki O, Sakamoto S, Fukuda A, Shigeta T, Nakazawa A, et al. The classification based on intrahepatic portal system for congenital portosystemic shunts. *J Pediatr Surg* 2015; 50: 688-95.
11. Stringer MD. The clinical anatomy of congenital portosystemic venous shunts. *Clin Anat* 2008; 21: 147-57.
12. Newman B, Feinstein JA, Cohen RA, Feingold B, Kreutzer J, Patel H, Chan FP. Congenital extrahepatic portosystemic shunt associated with heterotaxy and polysplenia. *Pediatr Radiol* 2010; 40: 1222-30.
13. Abernethy J. Account of two instances of uncommon formation in viscera of the human body. *Phil Trans R Soc* 1973; 83: 59-66.
14. Sharma R, Suddle A, Quaglia A, Peddu P, Karani J, Satyadas T, Heaton N. Congenital extrahepatic portosystemic shunt complicated by the development of hepatocellular carcinoma. *Hepatobiliary Pancreat Dis Int* 2015; 14: 552-7.
15. Hubert G, Giniès JL, Dabadie A, Tourtelier Y, Willot S, Pariente D, Lefrançois T, et al. [Congenital portosystemic shunts: experience of the western region of France over 5 years]. *Arch Pediatr* 2014; 21: 1187-94.
16. de Ville de Goyet J, Alberti D, Falchetti D, Rigamonti W, Matricardi L, Clapuyt P, Sokal EM, et al. Treatment of extrahepatic portal hypertension in children by mesenteric-to-left portal vein bypass: a new physiological procedure. *Eur J Surg* 1999; 165: 777-81.
17. Bambini DA, Superina R, Almond PS, Whittington PF, Alonso E. Experience with the Rex shunt (mesenterico-left portal bypass) in children with extrahepatic portal hypertension. *J Pediatr Surg* 2000; 35: 13-8.
18. Superina R, Shneider B, Emre S, Sarin S, de Ville de Goyet J. Surgical guidelines for the management of extrahepatic portal vein obstruction. *Pediatr Transplant* 2006; 10: 908-13.
19. Rahman N, Al-Nassar S, Davenport M. Congenital mesenterico-portal (Rex) shunt. *Pediatr Surg Int* 2002; 18: 514-6.

20. Grimaldi C, Adorisio O, di Francesco F, Goyet JV. Congenital Meso-Rex Bypass: A Rare and Remarkable Anatomical Variation of the Portal System. *J Pediatr Gastroenterol Nutr* 2017; 64: e49.
21. Komatsu S, Nagino M, Hayakawa N, Yamamoto H, Nimura Y. Congenital absence of portal venous system associated with a large inferior mesenteric-caval shunt: a case report. *Hepatogastroenterology* 1995; 42: 286-90.
22. Franchi-Abella S, Branchereau S. Benign hepatocellular tumors in children: focal nodular hyperplasia and hepatocellular adenoma. *Int J Hepatol* 2013; 2013: 215064.
23. Grimaldi C, Monti L, Falappa P, d'Ambrosio G, Manca A, de Ville de Goyet J. Congenital intrahepatic portohepatic shunt managed by interventional radiologic occlusion: a case report and literature review. *J Pediatr Surg* 2012; 47: e27-31.
24. Pupulim LF, Vullierme MP, Paradis V, Valla D, Terraz S, Vilgrain V. Congenital portosystemic shunts associated with liver tumours. *Clin Radiol* 2013; 68: e362-9.
25. Cho Y, Shimono T, Morikawa H, Shintaku H, Tokuhara D. Hepatic focal nodular hyperplasia with congenital portosystemic shunt. *Pediatr Int* 2014; 56: e102-5.
26. Cheon JE, Kim WS, Kim IO, Jang JJ, Seo JK, Yeon KM. Radiological features of focal nodular hyperplasia of the liver in children. *Pediatr Radiol* 1998; 28: 878-83.
27. Gupta P, Sinha A, Sodhi KS, Lal A, Debi U, Thapa BR, Khandelwal N. Congenital Extrahepatic Portosystemic Shunts: Spectrum of Findings on Ultrasound, Computed Tomography, and Magnetic Resonance Imaging. *Radiol Res Pract* 2015; 2015: 181958.
28. Scheuermann U, Foltys D, Otto G. Focal nodular hyperplasia precedes hepatocellular carcinoma in an adult with congenital absence of the portal vein. *Transpl Int* 2012; 25: e67-8.
29. Gong Y, Zhu H, Chen J, Chen Q, Ji M, Pa M, Zheng S, et al. Congenital portosystemic shunts with and without gastrointestinal bleeding - case series. *Pediatr Radiol* 2015; 45: 1964-71.
30. Alomari AI, Chaudry G, Fox VL, Fishman SJ, Buchmiller TL. Atypical manifestation of patent ductus venosus in a child: intervening against a paradoxical presentation. *J Vasc Interv Radiol* 2009; 20: 537-42.
31. Nagano K, Hoshino H, Nishimura D, Katada N, Sano H, Kato K. Patent ductus venosus. *J Gastroenterol Hepatol* 1999; 14: 285-8.
32. Strouse PJ, DiPietro MA. Persistent patency of the ductus venosus: consequence of portal hypertension in an infant? *J Ultrasound Med* 1997; 16: 559-61.
33. Barjon P, Lamarque JL, Michel H, Fourcade J, Mimran A, Giestie JF. Persistent ductus venosus without portal hypertension in a young alcoholic man. *Gut* 1972; 13: 982-5.
34. Wanless IR, Lentz JS, Roberts EA. Partial nodular transformation of liver in an adult with persistent ductus venosus. Review with hypothesis on pathogenesis. *Arch Pathol Lab Med* 1985; 109: 427-32.
35. Konstas AA, Digumarthy SR, Avery LL, Wallace KL, Lisovsky M, Misdradi J, Hahn PF. Congenital portosystemic shunts: imaging findings and clinical presentations in 11 patients. *Eur J Radiol* 2011; 80: 175-81.
36. Kim MJ, Ko JS, Seo JK, Yang HR, Chang JY, Kim GB, Cheon JE, et al. Clinical features of congenital portosystemic shunt in children. *Eur J Pediatr* 2012; 171: 395-400.

Correspondence and reprint request:

Maria Francelina Lopes, M.D., Ph.D.
Hospital Pediátrico, Centro Hospitalar e Universitário de
Coimbra. Avenida Afonso Romão, Santo António dos Olivais,
3000-602, Coimbra, Portugal.
Tel.: 00351 239 488700; Fax: 00351 239717216
E-mail: mfrancelina@yahoo.com