

# Pheochromocytoma: new paradigms for an old tumor

Duane T. Freier, MD. FACS,  
Michael K. McLeod, MD. FACS

## Abstract

**Objective:** The purpose is to bring attention to the continuing changes occurring in pheochromocytoma diagnosis, localization, blockade of its physiological effects, surgical excision, and management of recurrences.

**Data collection:** This is a review on the development of the identification and treatment of a rare but interesting tumor of chromaffin tissue that occurs throughout the body. The data is taken from highly selected references (18 references).

**Results:** An efficient screening technique for diagnosis, has not yet been developed. Sophisticated urinary and plasma studies are required. Localization has advanced remarkably with computerization of radiographic techniques and nuclear scanning. Blockade is very important, especially if laparoscopic excision is contemplated. There are few complications from it. Surgical excision has dramatically changed with laparoscopic techniques. Many recurrences respond to chemotherapy and nuclear medication obliteration after debulking.

**Conclusion:** Our overall conclusion is that treatment of this tumor requires constant study because all aspects are quickly changing as technology progresses.

**Key words:** Pheochromocytoma, diagnosis, localization, treatment.

**Cir Gen 2000;22:232-235**

## Resumen

**Objetivo:** Revisar los continuos cambios que ocurren en el feocromocitoma en su diagnóstico, localización, bloqueo de sus efectos fisiológicos, cirugía y manejo de la recurrencia.

**Selección de datos:** Se revisaron los principales artículos (18) acerca del desarrollo, identificación y tratamiento de este interesante tumor cromafínico.

**Resultados:** Se requiere una eficiente técnica de escrutinio para el diagnóstico, la localización del tumor ha progresado gracias a la tomografía computada y a las pruebas de medicina nuclear. El bloqueo fisiológico del tumor es importante, sobre todo si se contempla cirugía laparoscópica, la cual tiene pocas complicaciones. Las recurrencias responden a quimioterapia y aplicación de radioisotopos.

**Conclusión:** El tratamiento de este tumor requiere de una actualización continua por parte del cirujano, dado el rápido progreso en el diagnóstico y tratamiento del tumor.

**Palabras clave:** Feocromocitoma, diagnóstico, tratamiento.

**Cir Gen 2000;22:232-235**

From the Surgery Program, Michigan State University, College of Human Medicine. Kalamazoo Center for Medical Studies. Kalamazoo, Michigan, U.S.A.

Recibido para publicación: 20 de enero de 1999

Aceptado para publicación: 20 de marzo de 1999

Correspondencia: Duane T. Freier MD, FACS. Surgery Program. Michigan State University, Kalamazoo Center for Medical Studies 1000 Okland Drive, Kalamazoo, Michigan 49008. Phone: 616 337 62 60 Fax: 616 337 64 41, E-mail: freier@kcms.msu.edu

## History

The first pheochromocytomas were removed by Roux in Switzerland and C.H. Mayo in the Mayo Clinic in 1926. For the past 72 years the techniques of diagnosis, localization, and removal of these tumors have developed remarkably with many changes and options.

Diagnosis of these tumors by the biochemical measurement of urinary vanillylmandelic acid (VMA) has been a time honored method but is quite unreliable due to many interfering substances and poor sensitivity. Fluorescent techniques of identifying epinephrine, norepinephrine, metanephrine, and normetanephrine in the urine are also compromised by interfering substances and have given way to high pressure liquid chromatography, which accurately identifies these substances in urine and plasma.

Localization has passed through many stages of development from retroperitoneal air insufflation, intravenous pyelography, venography, arteriography, venous sampling, and more recently ultrasonography, computerized tomography, nuclear scanning with <sup>131</sup>I metaiodobenzylguanidine, magnetic resonance imaging (MRI), and positron emission tomography (PET) scanning.

Excision techniques have likewise gone through many stages of development. The "slash and grab" era has been replaced with careful dissection made possible by alpha and beta adrenergic receptor blockade, anesthetic agents that did not stimulate catecholamine receptors, and appropriate preoperative volume replacement. The anterior transabdominal and the posterior retroperitoneal open surgical approaches have both their advocates and their acceptable indications; but transabdominal and retroperitoneal laparoscopic approaches are now replacing them.

## Suspicion for discovery

Three clinical sources of pheochromocytoma discovery occur commonly. The first clinical scenario is the incidental finding of an adrenal mass in 0.5-10% of the computerized tomography scans (CT) of the abdomen obtained for other reasons. The biochemically verified tumors, the biochemically silent incidentalomas of > 3 cm or the biochemically silent tumors that grow under surveillance should be excised. Pheochromocytomas represent only 1% of all incidentalomas.<sup>1</sup> The second clinical scenario is screening patients with hypertension and typical symptoms, which have been an enigma for many years. Hypertension associated to the most common symptoms of pheochromocytoma, i.e., headaches, sweating and palpitations, occur very commonly; an efficient and inexpensive method of screening has not been developed.<sup>2</sup> And finally, the third clinical scenario is investigation of family members with multiple endocrine neoplasia, Type II. High genetic penetrance of the malady results in 50% occurrence in family cohorts. Family members with the disease have abnormalities in the adrenal medullary associated to a wide occurrence of histological alterations, varying from asymptomatic hyperplasia to functioning adenomas.

## Diagnosis

The standard urinary assessment for the diagnosis of a pheochromocytoma is the measurement of epinephrine, norepinephrine, metanephrine, normetanephrine, and vanillylmandelic acid (VMA).<sup>2</sup> Urinary metanephrine has been reliable and practical, with one report showing 100% sensitivity.<sup>3</sup> Measurement of metanephrine, normetanephrine, epinephrine, and norepinephrine in two resting overnight 12-hour samples has also been shown to have 100% sensitivity.<sup>4</sup> VMA studies have less than 80% sensitivity.

Measurement of serum epinephrine and norepinephrine has a sensitivity of 75-85%. Recently, free plasma metanephrines were shown to be elevated in all 52 patients with pheochromocytoma tumors.<sup>5</sup> Testing must be done with great care to prevent falsely positive results, but the convenience and reliability of a single blood drawing compared to a timed urinary collection is important.

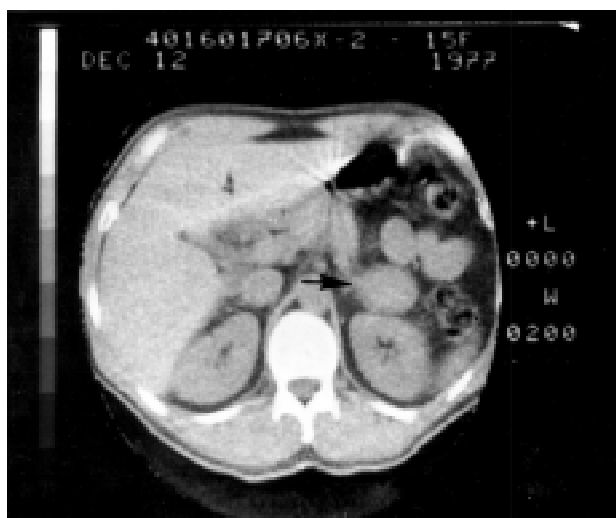
## Localization

Today computerized tomography is the most commonly used localization. **Figure 1** shows a left adrenal pheochromocytoma on CT scan.

Metaiodobenzylguanidine labelled with <sup>131</sup>I (MIBG scans) has been used to verify the presence of a pheochromocytoma. However, the sensitivity of a MIBG scan is 85-89%, especially if the tumor is extra-adrenal. The study itself is expensive and often not readily available.<sup>6</sup>

Magnetic resonance imaging (MRI) with T<sub>2</sub> weighting can differentiate pheochromocytomas from other adrenal tumors but not metastases.<sup>7</sup>

Ultrasound is an underutilized method to detect adrenal masses greater than 1 cm in size.<sup>8</sup> The application of this in pregnancy is especially important.<sup>9</sup>



**Fig. 1.** Computerized tomogram showing a prominent left adrenal tumor histologically proved to be a pheochromocytoma.

As mentioned above, CT scans are the accepted standard today for the localization of pheochromocytomas. A negative CT scan and a positive biochemical study should be followed by MIBG, MRI, or PET scanning. If the localization studies are all negative, then observation and repeated biochemical studies are in order.

### Blockade

Alpha adrenergic blockade with phenoxybenzamine or prazosin for 10 days, followed by beta blockade for 3-4 days are recommended for the preoperative preparation of pheochromocytomas.<sup>2</sup> The benefits far outweigh any risks of the medications. Plasma volume expansion during the blockade is also essential. Calcium channel blockers alone have been used with reported success but clear failures are also documented.<sup>10,11</sup>

### Excision

The development of laparoscopy has had a major effect on excision of adrenal tumors in general and on pheochromocytomas in particular. The anterior transabdominal laparoscopic approach that was utilized initially is already in disfavor. Lateral transabdominal and posterior retroperitoneal laparoscopic approaches are recommended.<sup>12</sup> Bilateral laparoscopic excisions are feasible. Postoperative lengths of stay are as short as 1 day and average 2-3 days. Intraoperative hypertension and hypotension have been reported in as many as 50% of cases, therefore adrenergic blockade is important.<sup>13</sup>

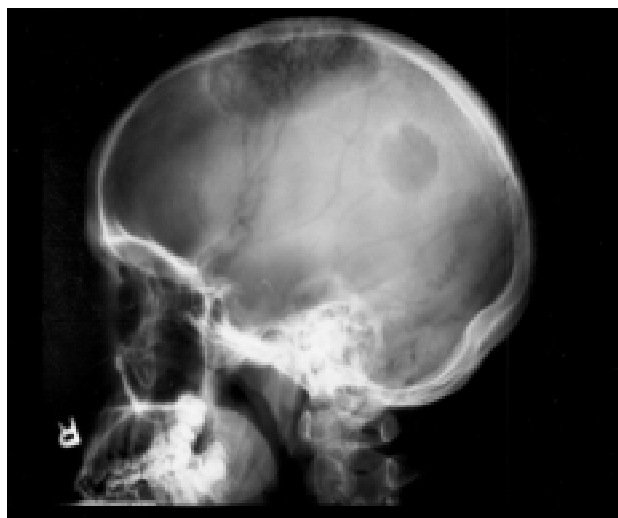
The classical open anterior approach is strongly defended by advocates who are concerned about the potential multifocality of these tumors, the potential for malignancy manifested by node involvement, and the occasional falsely negative MIBG scan.<sup>14</sup> Tumors larger than 10-15 cm, and previous operations in the area are additional indications for the open anterior approach.<sup>15</sup>

Utilizing the open posterior approach compared to the anterior has resulted in less morbidity (11-20% vs 23-53%), less blood loss, less operating time, and shorter postoperative hospital stay.<sup>16</sup> Tumors must be less than 5-8 cm in size and no malignancy can be suspected before a posterior approach is recommended.

### Recurrence

Recurrence rates of 7-10% make long term follow-up mandatory.<sup>15</sup> Recurrence is associated with MEN II disease, familial cases, pediatric patients, and patients with multiple tumors. Histology cannot reliably predict malignancy of pheochromocytomas.

The treatment of recurrences and metastases will require an individualized approach, utilizing surgical debulking combined with either<sup>131</sup>I MIBG treatment with a 25-30% partial response,<sup>17</sup> or chemotherapy (cyclophosphamide, vincristine, and dacarbazine) with approximately a 50% partial or complete response.<sup>18</sup> **Figure 2** shows a dramatic skull X-ray of a patient with pheochromocytoma metastases.



**Fig. 2.** Skull X-ray showing dramatic lesions in a patient with known pheochromocytoma recurrence.

### References

1. McLeod MK. Adrenal incidentaloma. *Acta Chirurg Austriaca* 1993; 25: 202.
2. Werbel SS, Over KP. Pheochromocytoma. Update on diagnosis, localization, and management. *Med Clin North Am* 1995; 79: 131-53.
3. Heron E, Chatellier G, Billaud E, Foos E, Plouin PF. The urinary metanefrine to diagnosis of pheochromocytoma [see comments]. *Ann Intern Med* 1996; 125: 300-3.
4. Freier DT, Harrison TS. Rigorous biochemical criteria for the diagnosis of pheochromocytoma. *J Surg Res* 1973; 14: 177-80.
5. Lenders JW, Keiser HR, Goldstein DS, Willemsen JJ, Friberg P, Jacobs MC, et al. Plasma metanephrines in the diagnosis of pheochromocytoma [see comments]. *Ann Intern Med* 1995; 123: 101-9.
6. Shapiro B, Sisson JC, Shulkin BL, Gross MD, Zempel S. The current status of meta-iodobenzylguanidine and related agents for the diagnosis of neuro-endocrine tumors. *Q J Nucl Med* 1995; 39(4 suppl 1): 3-8.
7. Peplinski GR, Morton JA. The predictive value of diagnostic tests for pheochromocytoma. *Surgery* 1994; 116: 1101-9; discussion 1109-10.
8. Schwerek WB, Gorg C, Gorg K, Restrepo IK. Adrenal pheochromocytoma: a broad spectrum of sonographic presentation. *J Ultrasound Med* 1994; 13: 517-21.
9. Freier DT, Thompson NW. Pheochromocytoma and pregnancy: The epitome of high risk. *Surgery* 1993; 114: 1148-52.
10. Proye C, Thevenin D, Cecat P, Pettillot P, Carnaille B, Verin P, et al. Exclusive use of calcium channel blockers in preoperative and intraoperative control of pheochromocytomas: Hemodynamics and free catecholamine assays in ten consecutive patients. *Surgery* 1989; 106: 1149-54.
11. Munro J, Hurlbert BJ, Hill GE. Calcium channel blockade and uncontrolled blood pressure during pheochromocytoma surgery. *Can J Anaesth* 1995; 42: 228-30.
12. Duh QY, Siperstein AE, Clark OH, Schechter WP, Horn JK, Harrison MR, et al. Laparoscopic adrenalectomy. Comparison of the lateral and posterior approach. *Arch Surg* 1996; 131: 870-5; discussion 867-9.

13. Gagner M, Breton G, Pharand DJ, Pomp A. Is laparoscopic adrenalectomy indicated for pheochromocytomas? *Surgery* 1996; 120: 1076-9; discussion 1079-80.
14. Orchard T, Grant CS, van Heerden JA, Weaver A. Pheochromocytoma continuing evolution of surgical therapy. *Surgery* 1993; 114: 1153-8; discussion 1158-9.
15. Obara T, Kanbe M, Okamoto T, Ito Y, Yamashita T, Ito K, et al. Surgical strategy for pheochromocytoma: emphasis on the pledge of flank extraperitoneal approach in selected patients. *Surgery* 1995; 118: 1083-9.
16. Irvin GL 3<sup>rd</sup>, Fishman LM, Sher JA, Yeung LK, Irani H. Pheochromocytoma: lateral versus anterior operative approach. *Ann Surg* 1989; 209: 774-8; discussion 778.
17. Shapiro B, Sisson JC, Shulkin BL, Gross MD, Zempel S. The current status of radioiodinated metaiodobenzylguanidine therapy of neuroendocrine tumors. *Q J Nucl Med* 1995; 39(4 suppl 1): 55-7.
18. Averbuch SD, Steakley CS, Young RC, Gelman EP, Goldstein DS, Stull R, et al. Malignant pheochromocytoma: effective treatment with a combination of cyclophosphamide, vincristine, and dacarbazine. *Ann Intern Med* 1988; 109: 267-73.