



Takotsubo syndrome in a cruise ship port, a single center experience

Síndrome de Takotsubo en un puerto de buques crucero, experiencia de un solo centro

Rafael Moguel Ancheita,^{*‡} Giovanni Ponte González,^{*‡}
Samady Berrones Homa,^{*‡,§} Krupal Reddy,[¶] Virginia Samaniego Méndez^{*}

Keywords:

Takotsubo syndrome, cruise ships, heart failure, cardiogenic shock, vacations.

Palabras clave:

síndrome de Takotsubo, cruceros, insuficiencia cardiaca, choque cardiogénico, vacaciones.

ABSTRACT

Introduction: Takotsubo syndrome is an infrequent problem characterized by transitory apical dilatation and ballooning of the left ventricle, frequently resulting from mental or physical stress; it mimics other acute cardiac problems. There are few publications about these conditions in vacation centers, especially on cruise ships. **Results:** the paper describes 15 patients from a vacation center with high cruise ship volume, from 2014 through 2023, nine of them on Killip-Kimbal class 3-4; the average ejection fraction of all patients was 36%. All the patients had negative coronary angiography or non-significant stenosis, and all of them had complete recovery before leaving the hospital, on Killip-Kimball class 1 and 58% average left ventricle ejection fraction. **Discussion and conclusion:** the present TS single-center experience at a top vacation cruise line center offers significant insight into travelers' triggers, demographic characteristics, and illness management. Post-menopause, women are especially vulnerable to the syndrome. TS usually shows ST-segment but is distinguished from acute coronary syndromes by the early return of ventricular function, conditions observed in our patients. Echocardiography, coronary angiography, and electrocardiography are vital for distinguishing myocardial infarction from TS. Supportive therapy and identifying and correcting triggering variables are part of the management; this care may include intravenous and device-based ventricular support.

RESUMEN

Introducción: el síndrome de Takotsubo es un problema poco frecuente que se caracteriza por la dilatación apical transitoria y el abombamiento del ventrículo izquierdo, que suele ser consecuencia del estrés físico o mental; imita otros problemas cardíacos agudos. Existen pocas publicaciones sobre estas afecciones en centros vacacionales, especialmente en cruceros. **Resultados:** el artículo describe 15 pacientes de un centro vacacional con un gran volumen de cruceros, desde 2014 hasta 2023, nueve de ellos con una clase Killip-Kimbal 3-4; la fracción de eyección promedio de todos los pacientes fue del 36%. Todos los pacientes tenían una angiografía coronaria negativa o estenosis no significativa y todos se recuperaron por completo antes de salir del hospital, con una clase Killip-Kimball 1 y una fracción de eyección promedio del ventrículo izquierdo del 58%. **Discusión y conclusión:** la experiencia actual de un solo centro de TS en un centro de una importante línea de cruceros vacacionales ofrece una perspectiva significativa sobre los desencadenantes de los viajeros, las características demográficas y el manejo de la enfermedad. Después de la menopausia, las mujeres son especialmente vulnerables al síndrome. El síndrome de Tourette suele mostrar segmento ST, pero se distingue de los síndromes coronarios agudos por el retorno temprano de la función ventricular, condiciones observadas en nuestros pacientes. La ecocardiografía, la angiografía coronaria y la electrocardiografía son vitales para distinguir el infarto de miocardio del síndrome de Tourette. La terapia de apoyo y la identificación y corrección de las variables desencadenantes son parte del tratamiento; esta atención puede incluir asistencia ventricular intravenosa y basada en dispositivos.

* The Clinics of the Heart, Cozumel, Quintana Roo México.
‡ COSTAMED. Quintana Roo, Mexico.
§ Universidad Anáhuac Cancun. Cancun, Quintana Roo, Mexico.
¶ Zulekha Hospital Dubai. Dubai, United Arab Emirates.

Received:
10/15/2024
Accepted:
11/28/2024

How to cite: Moguel AR, Ponte GG, Berrones HS, Reddy K, Samaniego MV. Takotsubo syndrome in a cruise ship port, a single center experience. *Cardiovasc Metab Sci.* 2024; 35 (4): 145-150. <https://dx.doi.org/10.35366/118791>

INTRODUCTION

Takotsubo syndrome (TS) consists of sudden functional deterioration and deformity of the left ventricle, typically with apical segment dyskinesia and ballooning, with the preservation of the basal segment's mobility. It frequently results after a mental or physical stressing condition, especially in women, under complex pathophysiological aspects such as paradoxical adrenergic-load triggered myocardial microvascular dysfunction, stress-triggered altered neuronal activity, metabolic derangements, and epigenetics.^{1,2}

This kind of cardiomyopathy mimics other acute cardiac problems, especially myocardial infarction, and myocarditis, with all the possible heart failure spectrum up to cardiogenic shock, cardiac arrest, and death, being sometimes unrecognized and making particular diagnostic challenges, with its final clinical diagnostic feature, the complete or almost complete quick left ventricle function and shape recovery.

The mental stress triggering TS might result from a sad personal catastrophe, extreme joy, physical trauma, or general disease; nonetheless, sometimes, there is a lack of stress. The present paper discloses our experience of TS in patients who attended a hospital located in a port that receives cruise-ship travelers. Up to these cases, there is only one published case of a woman suffering from TS on a cruise ship.³

TS, which primarily affects postmenopausal women, represents 1-2% of all suspected cases of acute coronary syndrome. While most patients with TS recover fully, complications can occasionally result in significant morbidity and mortality.⁴

MATERIAL AND METHODS

Our private hospital attends to the local population, destination tourists, and cruise ship travelers. The current paper is a case report resulting from the retrospective review of our patients considered with a diagnosis of TS, based on the occurrence of sudden myocardial infarction symptoms and heart failure, with echocardiography-tailored transitory segmental akinesia with angiography-confirmed lack of significant coronary stenosis and documented

clinical and echocardiography recovery before discharge. Our experience includes a small case number from a low-volume heart service, with results expressed as case presentations with an average of the numerical variables.

RESULTS

We gathered data from 12 women and two men—one of them is a ship crew member—with TS between 2014 and 2023. Their average age was 61.8 years, with an average hospital stay of 4.9 days and an average body mass index of 29.5. Ten patients were from cruise ships, three were tourists, and one was a local patient. Nine patients were on Killip-Kimbal class 3-4 and five class 1-2, with an average class of 2.7.

The average ejection fraction at admission was 36%; seven patients started with chest pain, 12 had dyspnea, three had delirium, three patients needed mechanical invasive ventilation, while four on cardiogenic shock received intravenous amines, none of them had mechanical cardiac support. Only three patients had initial ST elevation, two had left bundle branch block, 12 had troponin I, and 12 had proBNP elevation. We found three patients with mental stress before the event, and eight had physical trauma: three during snorkeling, one on scuba diving, one during beach gaming, one after intense diarrhea, one after severe bladder retention, and one during abdominal sepsis. Four patients had a history of depression, one of them after melanoma.

All the patients had coronary angiography, eleven catheter-based and three by computed tomography; 12 had coronaries without significant and two with borderline stenosis; nine catheterized patients had TIMI-3 and two TIMI-2 flow. All the patients left the hospital (four by air-ambulance transfer, ten to home) on Killip-Kimbal class 1; the discharge ejection-fraction average was 58.4%.

Table 1 shows the patients' origin and demographics. *Table 2* shows the basal patient's characteristics, and *Table 3* displays the diagnostic angiography and outcomes; *Figure 1* displays the Killip-Kimbal class progress and *Figure 2* the ejection fraction; *Figure 3* shows an example of the echocardiographic in one of our patients, showing the characteristic apical

Table 1: Patient demographics and medical history.

Patient	Sex	Age (years)	Origin	Weight (kg)	Height (cm)	BMI	DM	HTN	Depression	Smoking	Previous heart disease
1	F	59	Cruise	80	172	27	No	Yes	Yes	Yes	No
2	F	83	Local	69	148	31	Yes	Yes	No	No	Yes
3	F	73	Cruise	91	152	39	No	Yes	No	No	No
4	M	34	Cruise	87	168	31	No	No	No	No	No
5	F	68	Cruise	113	170	39	No	Yes	Yes	No	Yes
6	M	79	Cruise	81	171	28	No	No	No	No	Yes
7	M	58	Germany	68	168	24	Yes	Yes	No	No	No
8	F	51	Canada	92	175	30	No	No	No	No	No
9	F	68	Cruise	85	170	29	Yes	No	Yes	No	Yes
10	M	24	Cruise	83	178	26	No	No	No	No	No
11	F	60	Cruise	NA	NA	NA	No	No	No	No	No
12	F	75	Argentina	70	155	29	No	Yes	No	No	No
13	M	59	Cruise	93	175	30	No	Yes	No	No	Yes
14	F	75	Cruise	50	152	21	No	No	Yes	No	No

BMI = body mass index. DM = diabetes mellitus. F = female. HTN = hypertension. M = male.

Table 2: Clinical presentation and laboratory.

	Angina	Dyspnea	Ventilation	Emotional trauma	Trauma etiology	Troponin elevated	proBNP elevated	ST elevation	Initial KK	Final KK	Admission ejection fraction	Discharge ejection fraction
1	Yes	Yes	Yes	Yes	Excursion	Yes	Yes	No	4	1	25	72
2	No	Yes	Yes	No	No	No	Yes	No	3	1	30	50
3	No	Yes	No	No	Snorkel	Yes	Yes	No	1	1	73	73
4	Yes	Yes	Yes	No	No	Yes	Yes	No	4	1	15	52
5	Yes	Yes	No	Yes	No	Yes	Yes	No	3	1	50	50
6	No	No	No	No	No	Yes	No	No	1	1	64	67
7	Yes	Yes	Yes	No	Snorkel	Yes	No	No	1	1	38	70
8	Yes	Yes	No	No	Scuba diving	Yes	Yes	Yes	3	1	28	50
9	Yes	Yes	No	No	No	Yes	Yes	No*	3	1	25	44
10	Yes	Yes	No	No	Sepsis	Yes	Yes	Yes	2	1	20	40
11	No	Yes	No	No	Beach playing	Yes	Yes	Yes	3	1	25	60
12	No	Yes	No	No	No	Yes	Yes	Yes	4	1	25	55
13	No	No	No	No	Urination pain	Yes	Yes	No*	2	1	55	66
14	No	Yes	Yes	Yes	Snorkel	No	Yes	No	4	1	32	68

* Left bundle branch block. KK = Killip-Kimbal class.

ballooning on dotted lines and the typical basal contractility shown by the arrows.

DISCUSSION

The present TS single-center experience at a top vacation cruise line center offers significant insight into travelers' triggers, demographic characteristics, and illness management. Any major changes in circumstances that are stressful for the person might also serve as triggers for the beginning of TS; significant atmosphere changes caused by lengthy overseas travels, together

with physical and psychological history, may significantly contribute to TS.⁵

Post-menopause, women are especially vulnerable to the syndrome due to hormonal fluctuations that intensify stress responses and endothelial impairment, possibly after the expected estrogen levels decline with consequent morbid changes in autonomic regulation and endothelial function, impairing the cardiovascular stress response.⁶

Myocardial stunning, microvascular dysfunction, and catecholamine surges are all implicated in the pathophysiology of TS,

Table 3: Procedures and outcome.

Patient	Coronary angiogram	Coronary stenosis	TIMI flow	Days of stay	Discharge
1	Invasive	Non-significant	2	2	Air ambulance
2	Invasive	Non-significant	3	13	Home
3	Computed tomography	Non-significant		4	Home
4	Invasive	Non-significant	3	13	Home
5	Invasive	Non-significant	3	1	Air ambulance
6	Invasive	Borderline	3	4	Home
7	Computed tomography	Non-significant		3	Home
8	Computed tomography	Non-significant		4	Home
9	Invasive	Non-significant	3	0	Home
10	Invasive	Non-significant	3	3	Home
11	Invasive	Non-significant	2	4	Air ambulance
12	Invasive	Non-significant	3	9	Home
13	Invasive	Borderline	3	3	Home
14	Invasive	Non-significant	3	6	Home

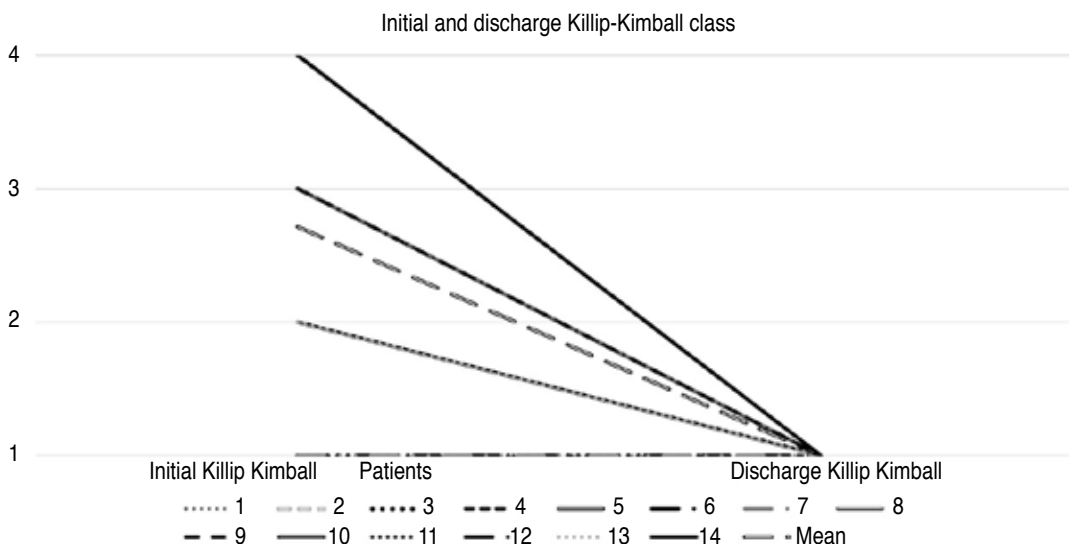


Figure 1:

The graphic displays every patient's Killip-Kimball class on admission and discharge.

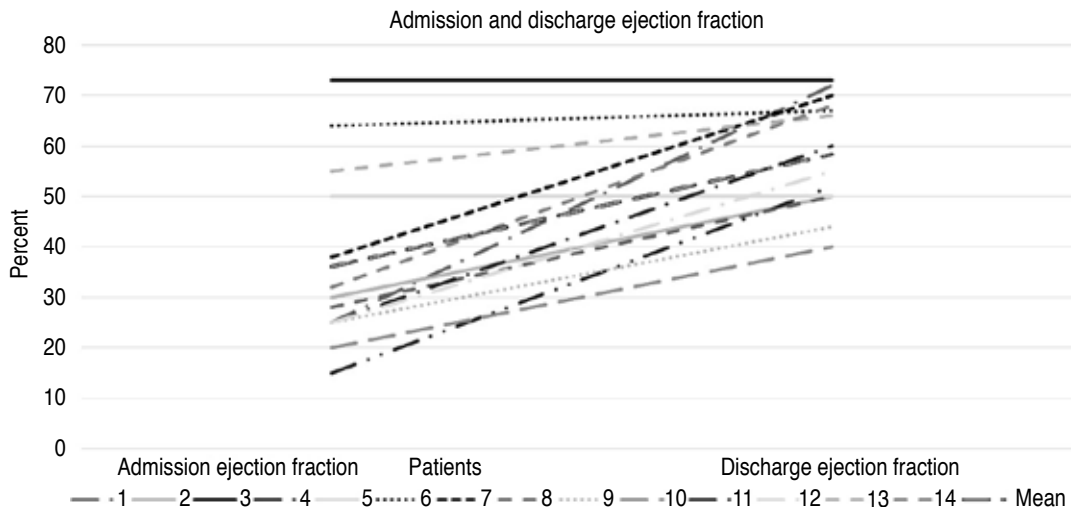


Figure 2:

The graphic displays every patient's ejection fraction on admission and discharge.

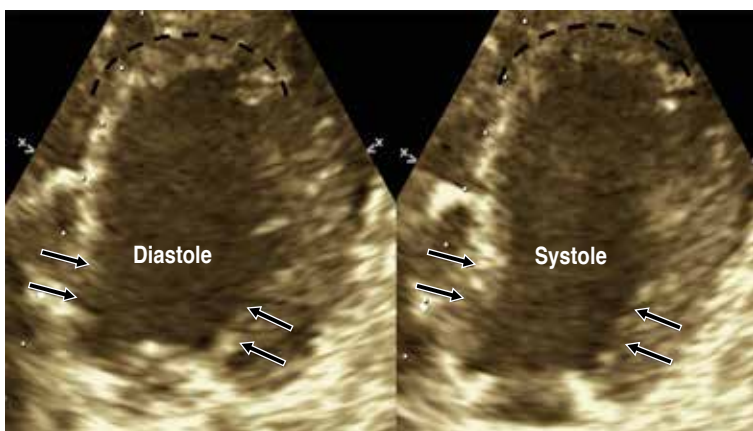


Figure 3: Typical left ventricle ballooning on systole and diastole, the arrows show the basal segments contractility, and the dotted lines show the apical ballooning.

possibly for dysregulation of the hypothalamic-pituitary-adrenal axis, which leads to increased sympathetic response and, in turn, left ventricular dysfunction.⁷

TS usually shows ST-segment elevation, dyspnea, and chest discomfort that resembles myocardial infarction, as well as presenting with any degree of heart failure, including cardiogenic shock, but distinguished from acute coronary syndromes by the early return of ventricular function, conditions observed in our patients.

Echocardiography, coronary angiography, and electrocardiography are vital for distinguishing myocardial infarction from

TS. Supportive therapy and identifying and correcting triggering variables are part of the management; this care may include intravenous and device-based ventricular support.

Even though the majority of patients restore their ventricular function on their own in a matter of days to weeks, persistent psychological stress could increase the chance of recurrence worth preventive strategies for TS recurrence, including neurohormonal therapies that target the sympathetic nervous system. In our patient list, we do not describe another three patients who came for cardiological assessment due to TS preexistence.

CONCLUSIONS

In conclusion, this single-center experience underscores the need for heightened vigilance in diagnosing and managing TS, particularly in high-stress settings like sea travel, warranting further research to explore the long-term outcomes of TS and the efficacy of stress management interventions in preventing recurrence.

REFERENCES

1. Singh T, Khan H, Gamble DT, Scally C, Newby DE, Dawson D. Takotsubo syndrome: pathophysiology, emerging concepts, and clinical implications. *Circulation*. 2022; 145 (13): 1002-1019. doi: 10.1161/CIRCULATIONAHA.121.055854.
2. Ferradini V, Vacca D, Belmonte B, Mango R, Scola L, Novelli G et al. Genetic and epigenetic factors of

- Takotsubo syndrome: a systematic review. *Int J Mol Sci.* 2021; 22 (18): 9875. doi: 10.3390/ijms22189875.
3. Taylor C. A “broken heart” on a cruise ship. *Int Marit Health.* 2015; 66 (1): 25-27. doi: 10.5603/IMH.2015.0007.
 4. Templin C, Ghadri JR, Diekmann J, Napp LC, et al. Clinical features and outcomes of Takotsubo (stress) cardiomyopathy. *N Engl J Med.* 2015; 373 (10): 929-938. doi: 10.1056/NEJMoa1406761.
 5. Frank N, Herrmann MJ, Lauer M, Forster CY. Exploratory review of the Takotsubo syndrome and the possible role of the psychosocial stress response and inflammaging. *Biomolecules.* 2024; 14 (2): 167. doi: 10.3390/biom14020167.
 6. Pelliccia F, Kaski JC, Crea F, Camici PG. Pathophysiology of Takotsubo syndrome. *Circulation.* 2017; 135 (24): 2426-2441. doi: 10.1161/CIRCULATIONAHA.116.027121.
 7. Frangieh AH, Obeid S, Ghadri JR, Imori Y et al; InterTAK collaborators. ECG criteria to differentiate between Takotsubo (stress) cardiomyopathy and myocardial infarction. *J Am Heart Assoc.* 2016; 5 (6): e003418. doi: 10.1161/JAHA.116.003418.

Declaration of confidentiality and patients consent: the authors confirm that they have complied with the relevant workplace protocols

for the use of patient data. Additionally, the authors attest that no form of generative artificial intelligence was employed in the preparation of this manuscript or in the creation of figures, graphs, tables, or their corresponding captions or legends.

Clinical trial registration and approval number: this is a retrospective observational experience, not a clinical trial.

Funding: no funding.

Declaration of interests: the authors declare no conflict of interest.

Acknowledgement: the authors want to thank the staff of COSTAMED and The Clinics of the Heart, the Universidad Anahuac social service program, and the mentor/mentee program of the Society for Cardiovascular Angiography and Interventions (SCAI).

Correspondence:

Rafael Moguel Ancheita

E-mail: cathboss@gmail.com